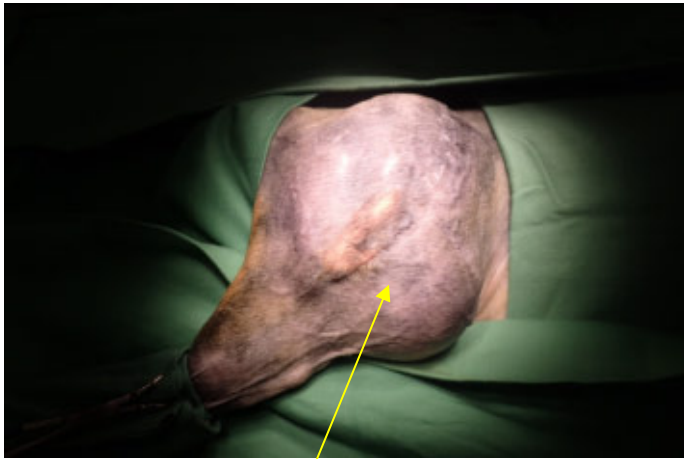
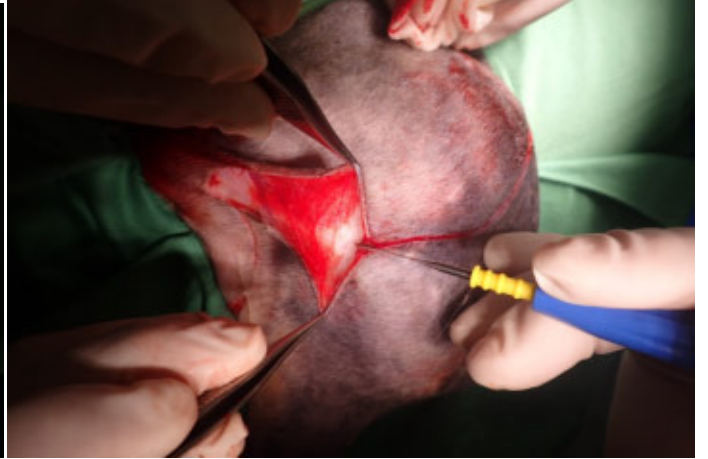

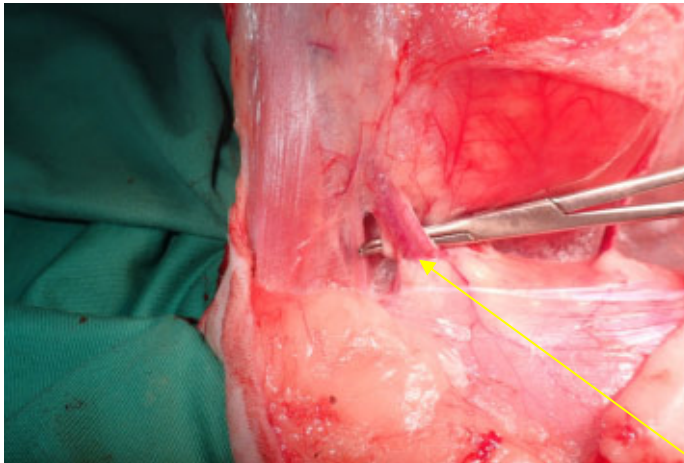
右後肢断脚手術



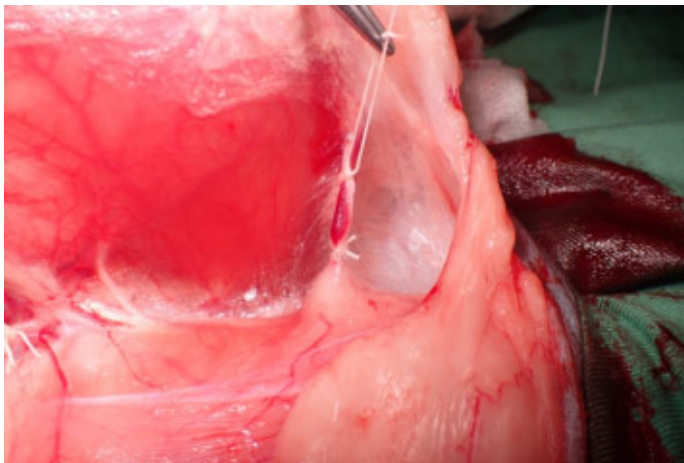
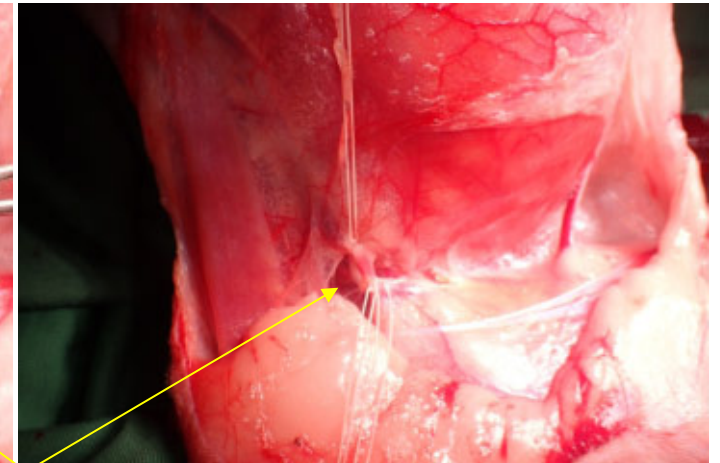
腫瘍



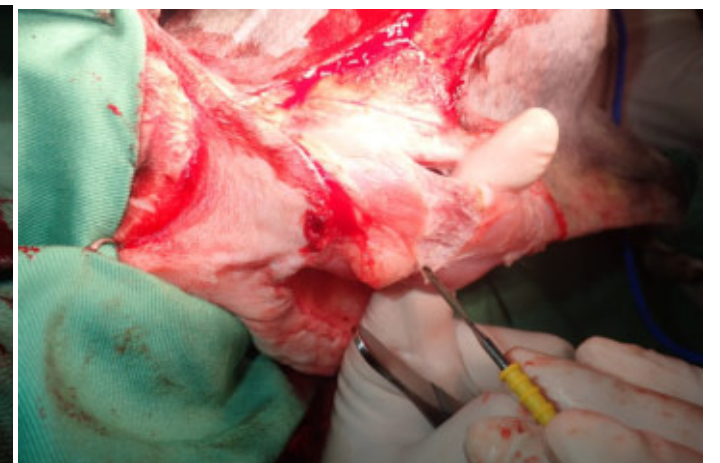皮膚切開後電気メスにて皮下組織を切開



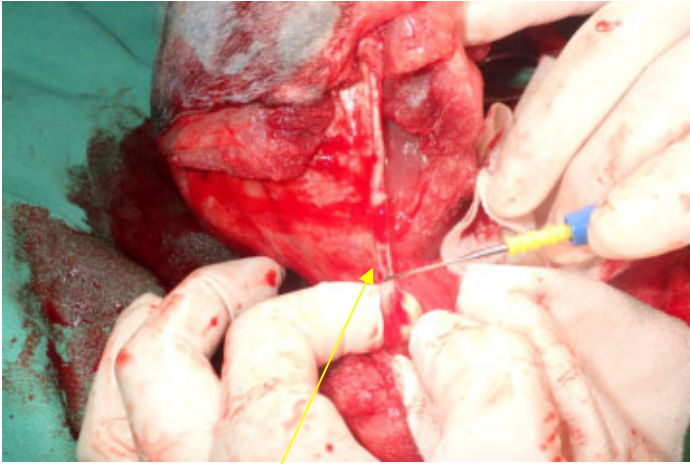
大腿動脈を結紮離断



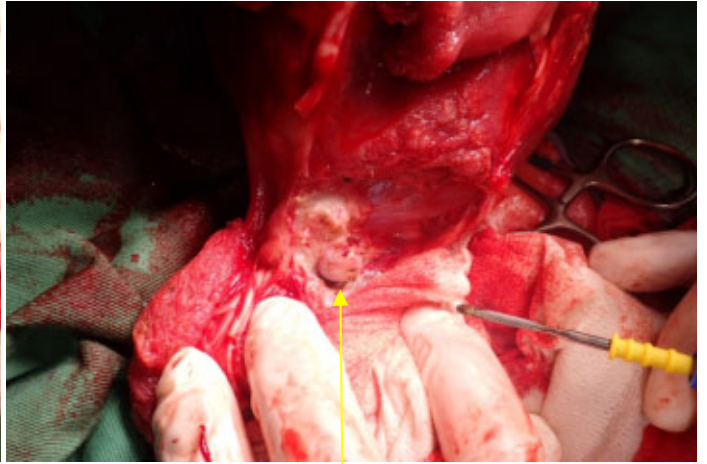
腫瘍血管



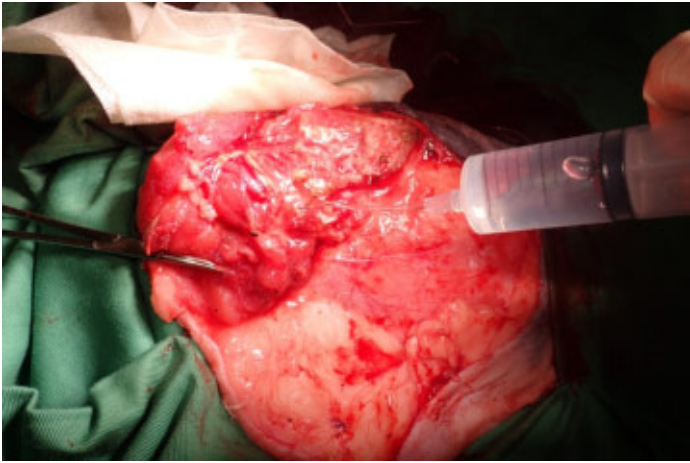
周囲の筋肉を切断



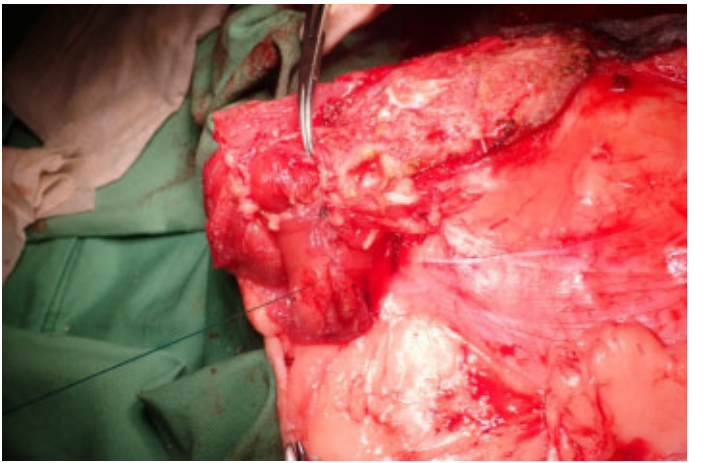
坐骨神経



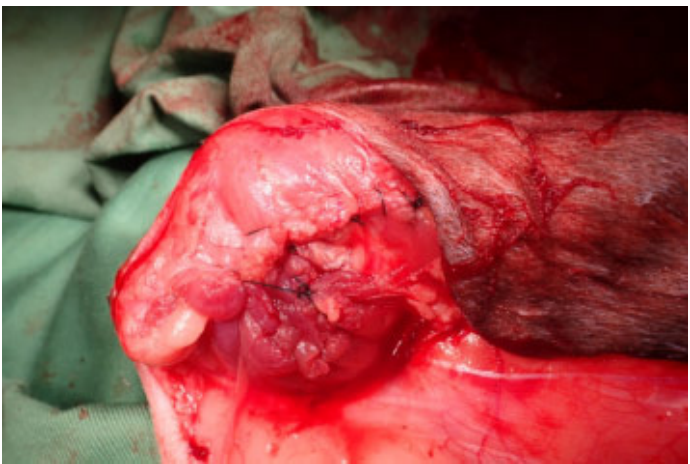
股関節靭帯を切断



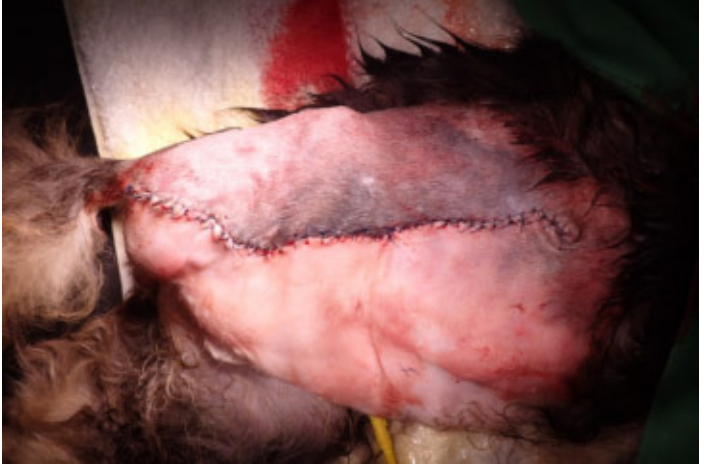切除後洗浄

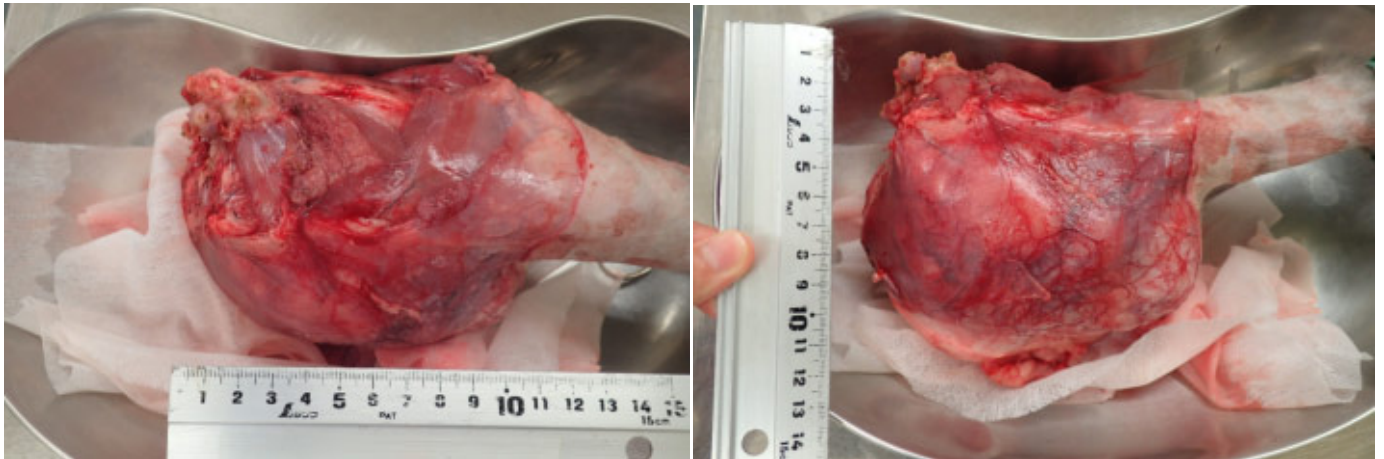


筋肉断端部を縫合



縫合終了 大腿動脈





正常組織と皮膜を含めて腫瘍を切除