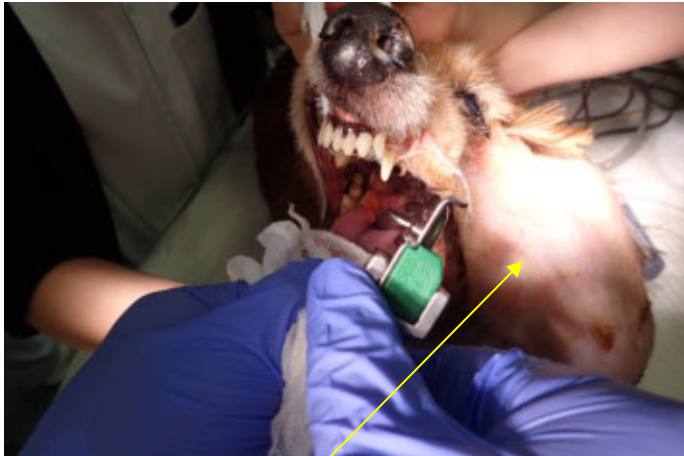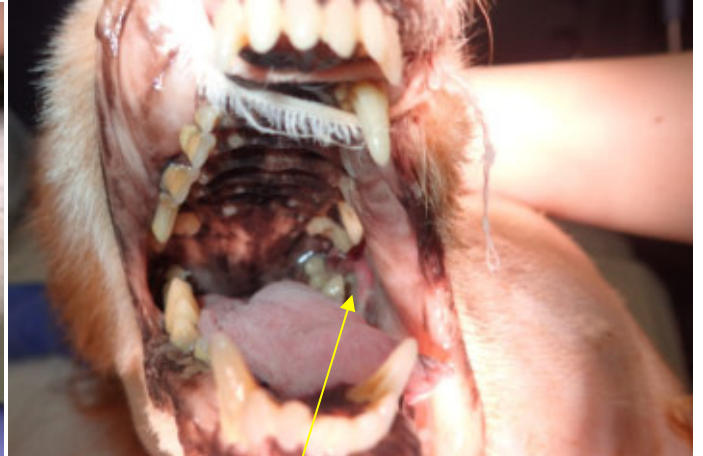


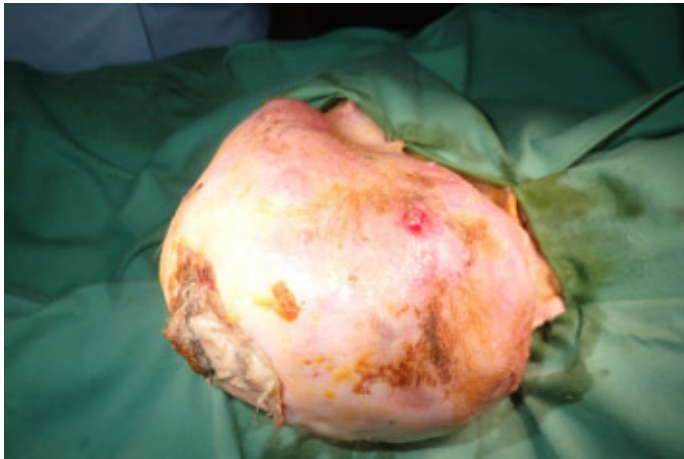
## 左頸部腫瘍切除手術



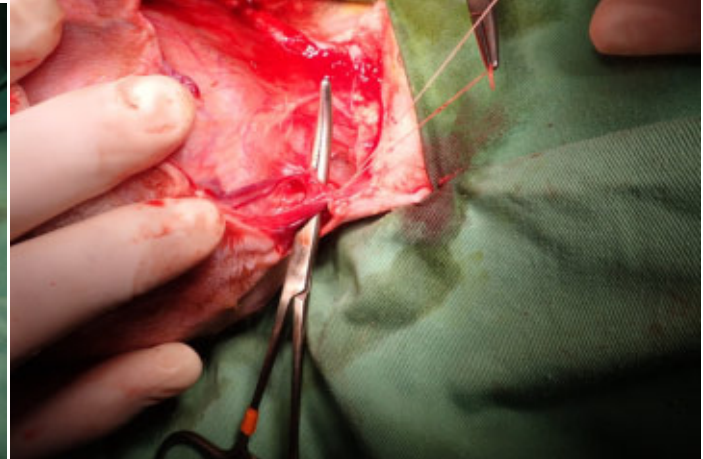腫瘍



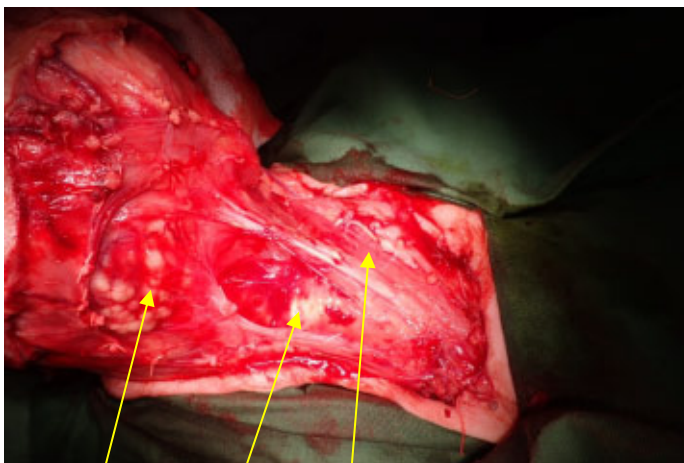
口腔軟膜へ腫瘍浸潤



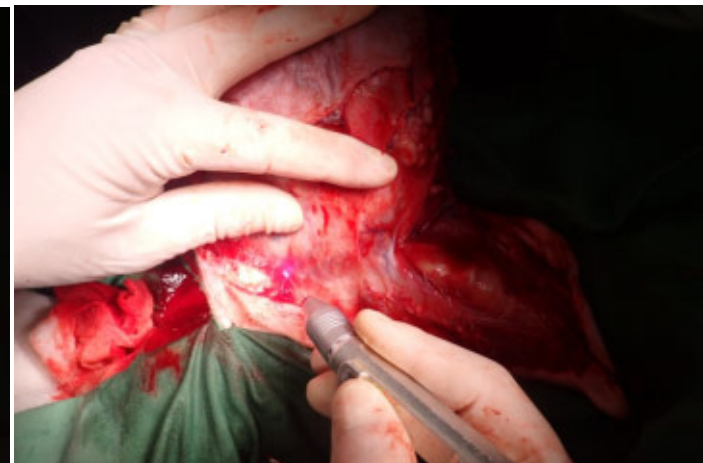腫瘍



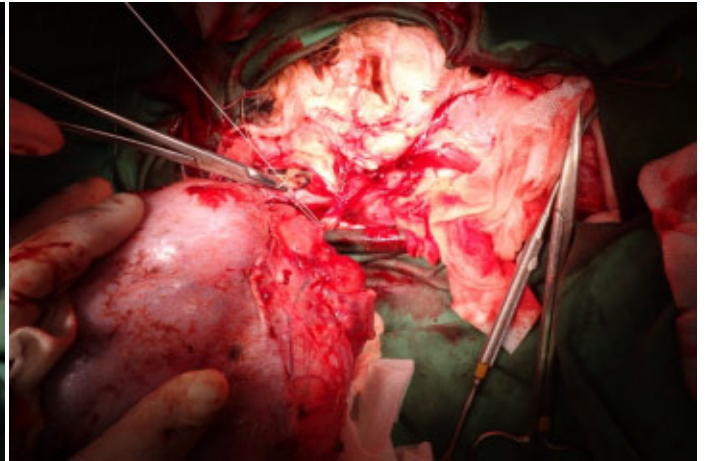
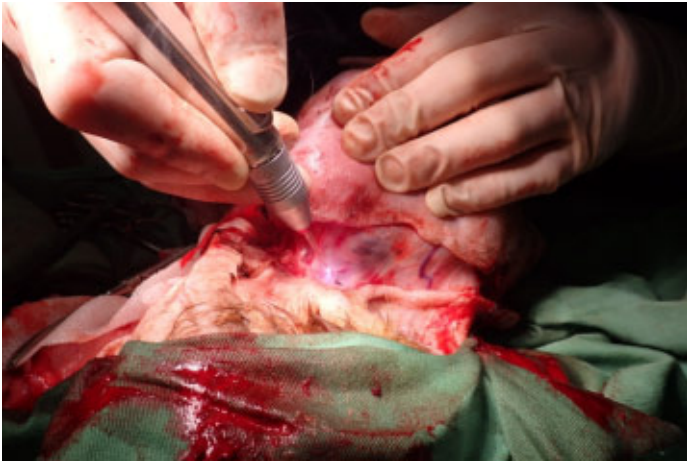
腫瘍血管の結紮離断の繰り返し



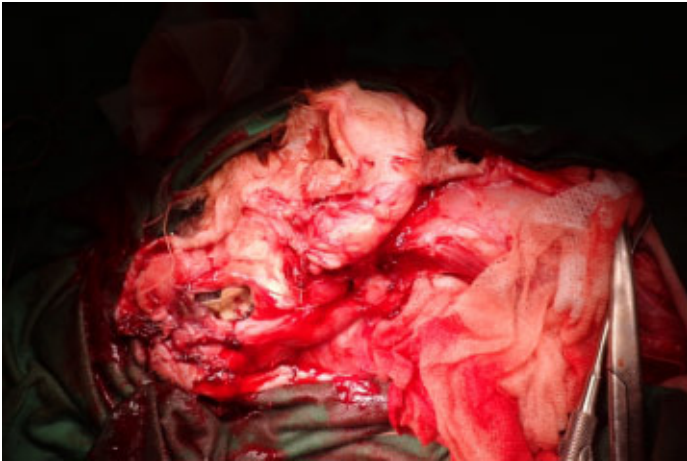
腫瘍 気管 頸静脈



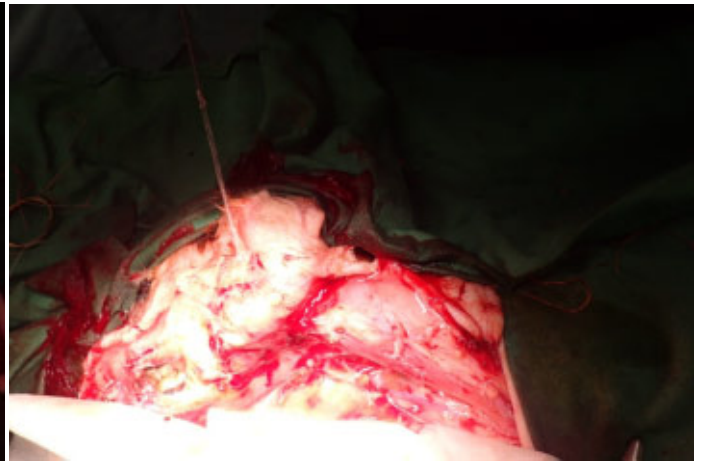
血管の少ないところはレーザーメスで切開



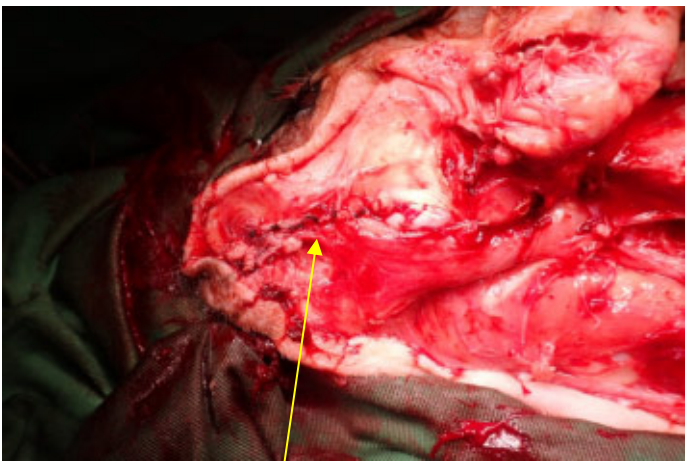
腫瘍底部



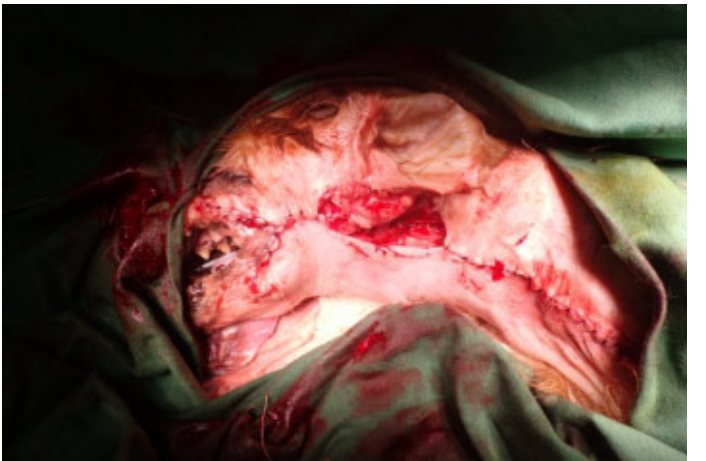切除終了



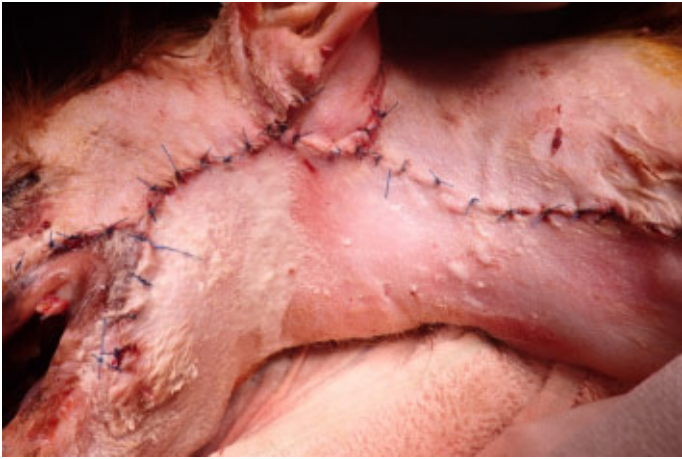洗浄



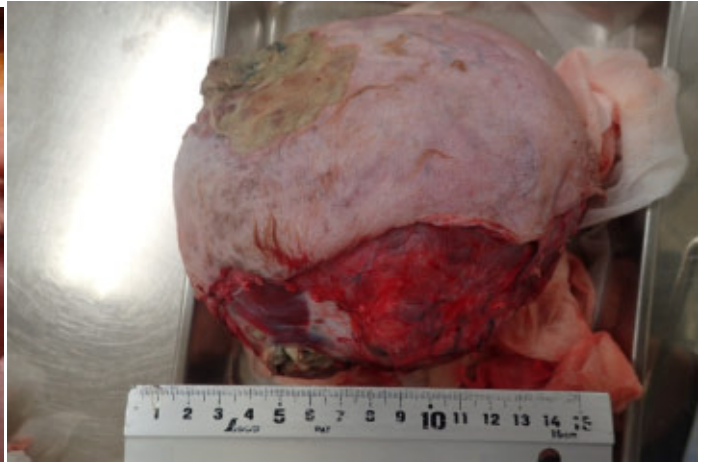口腔粘膜縫合



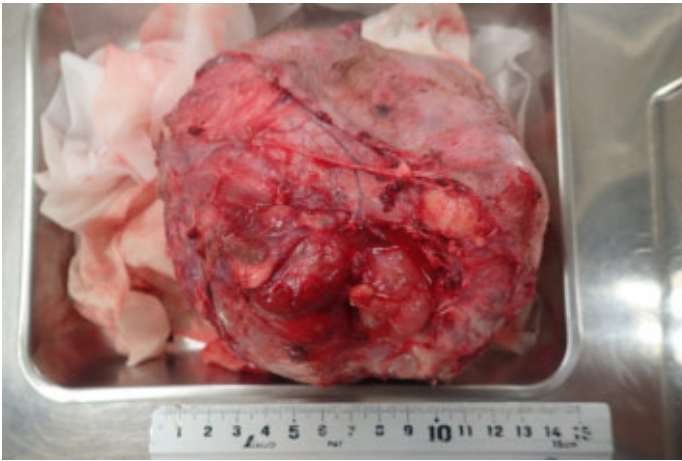皮膚縫合



縫合終了



摘出腫瘍 (1.8 k g)



摘出腫瘍底部