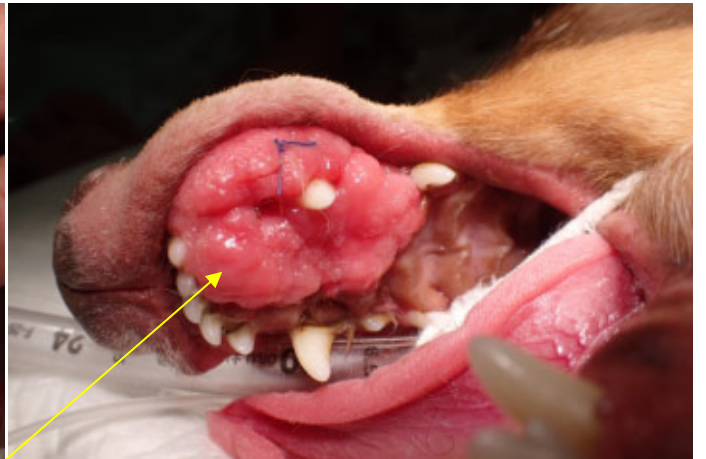
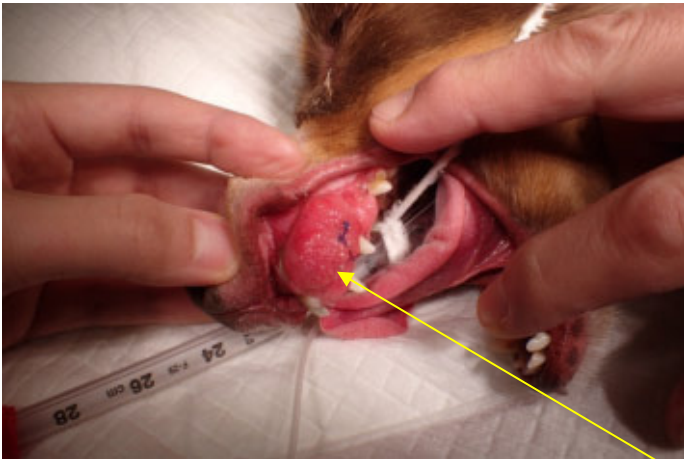
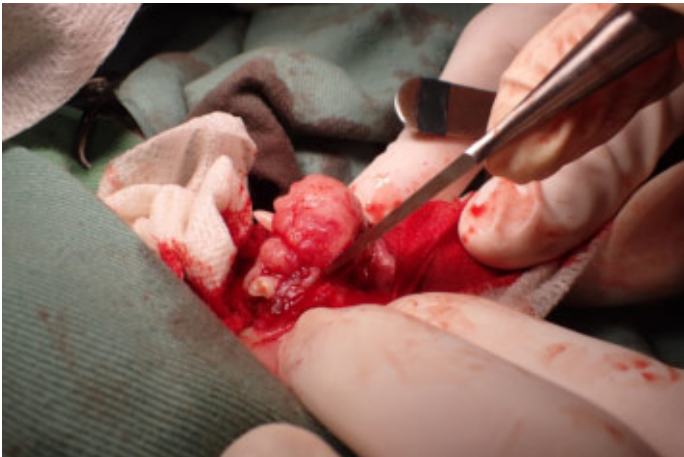

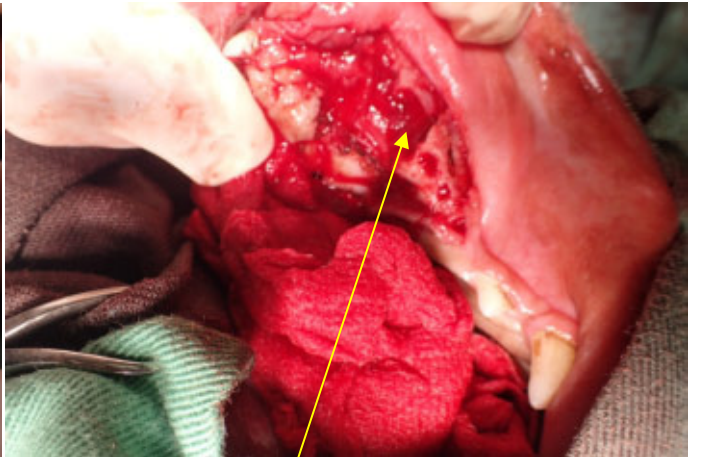
左上顎腫瘍切除手術



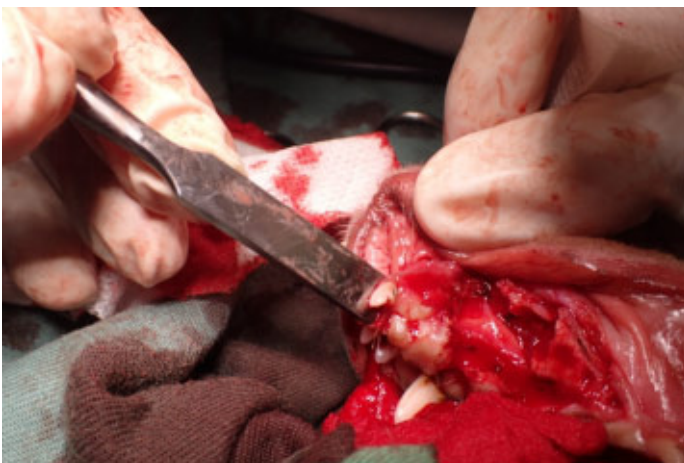腫瘍



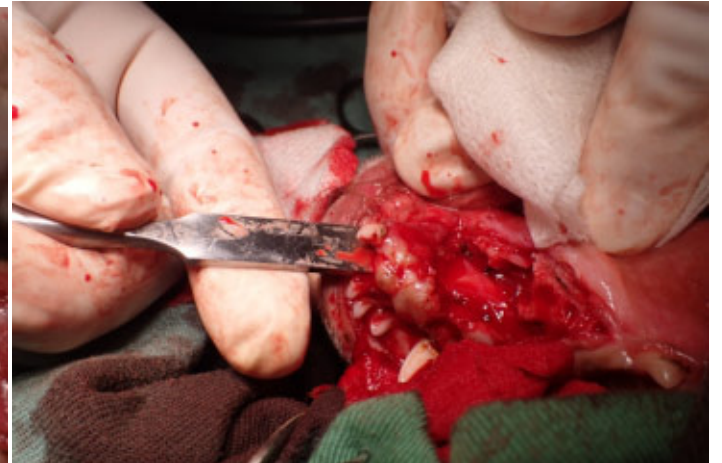
上顎腫瘍尾側方向より骨ノミにて上顎骨ごと切除

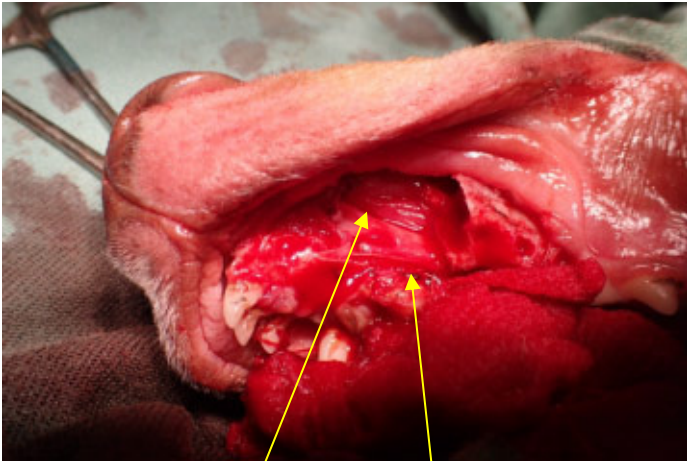


鼻腔貫通

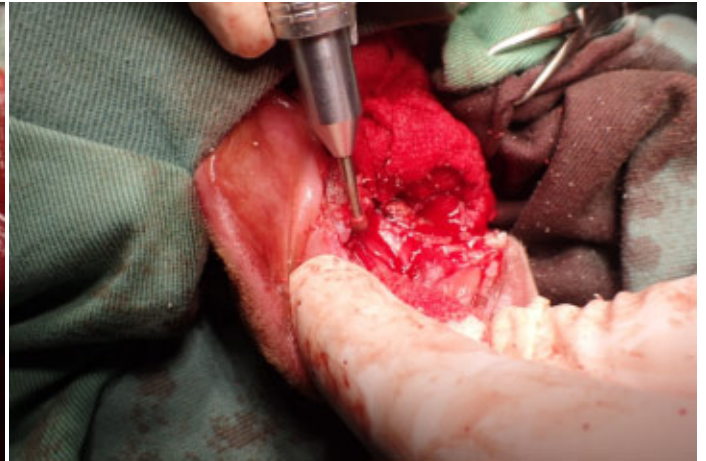

切歯の腫瘍を骨ノミにて切除

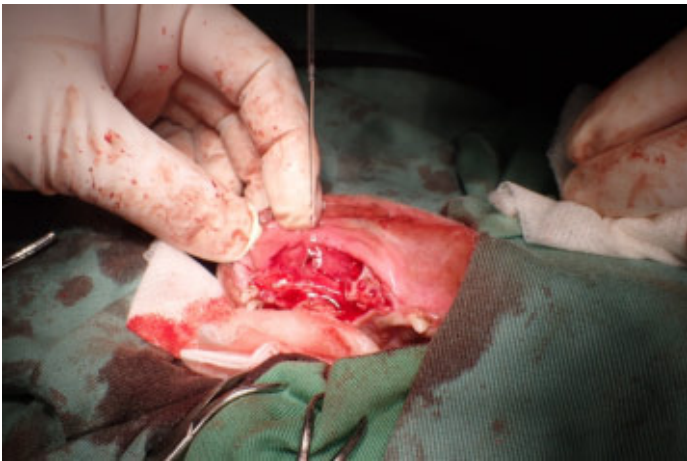




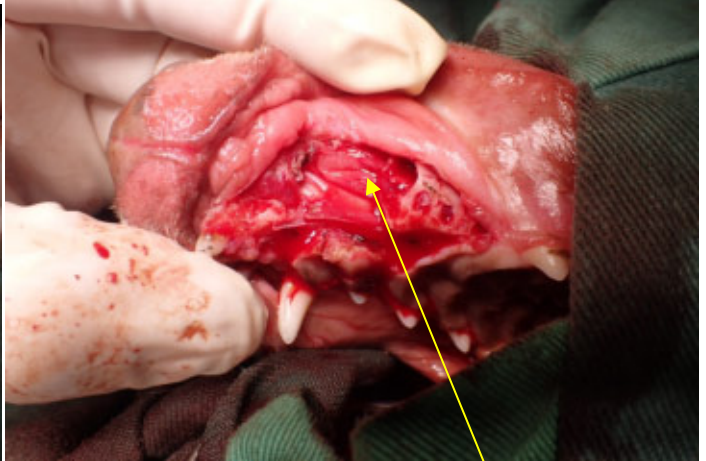
鼻腔内 上顎プレート



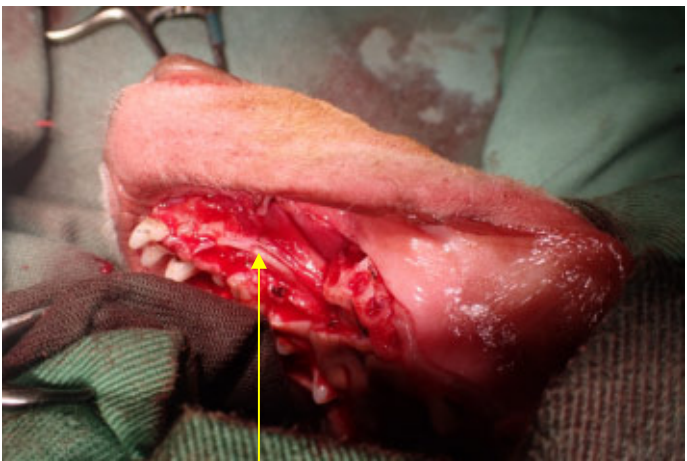
前臼歯切除辺縁を円形に形成



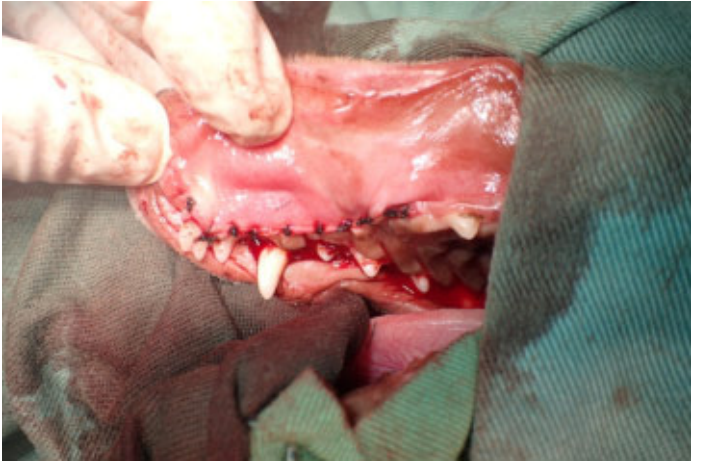腫瘍部位の洗浄



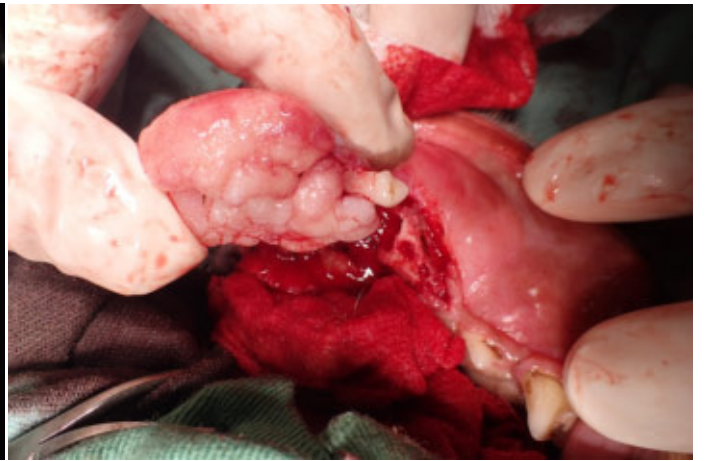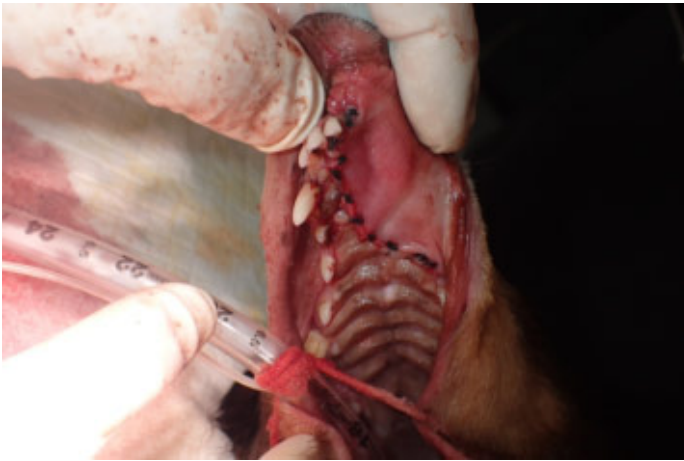洗浄後 鼻腔粘膜



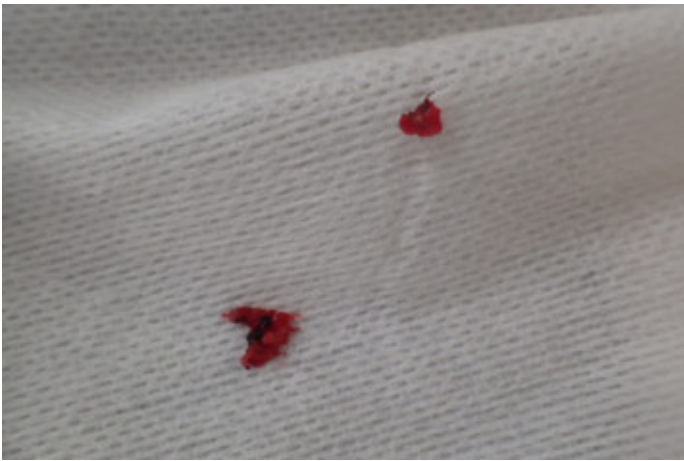上顎プレート



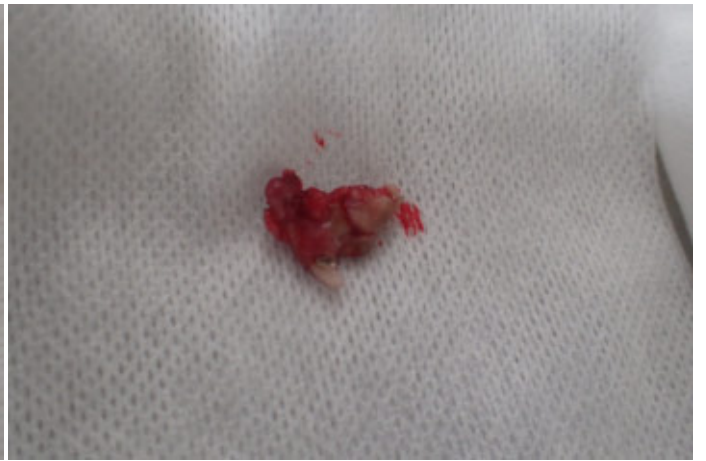口唇粘膜フラップ縫合終了



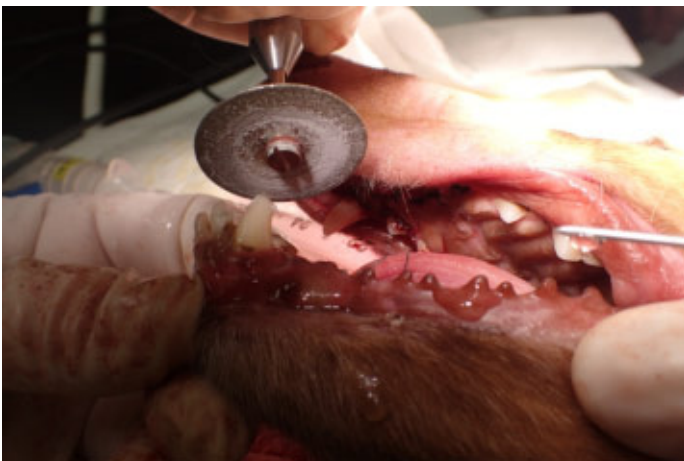上顎腫瘍



鼻腔切除粘膜



前方上顎腫瘍



右下顎犬歯先端を丸く研磨

