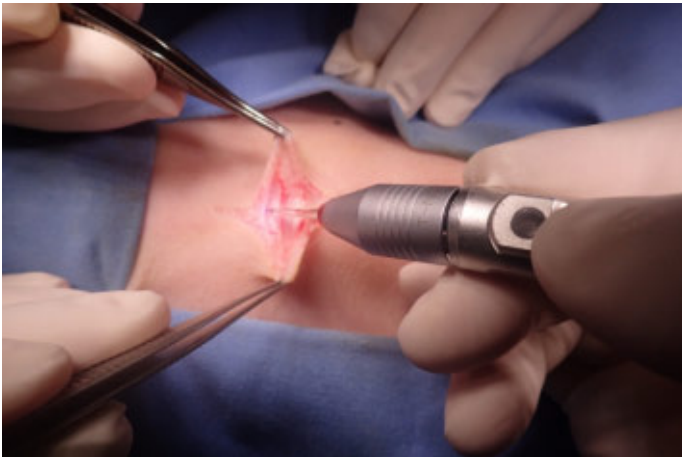
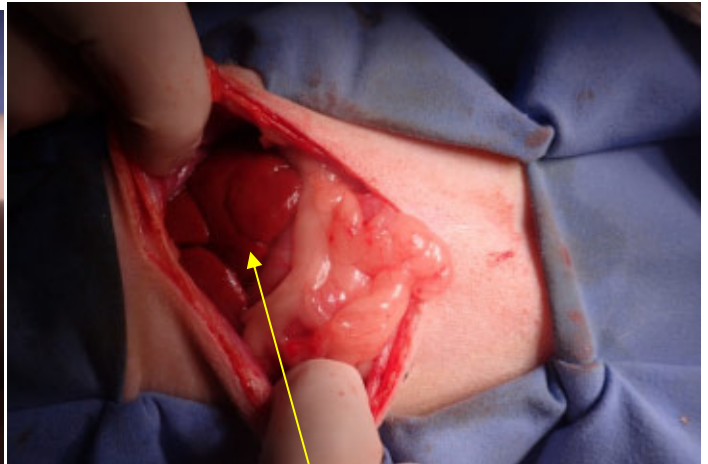


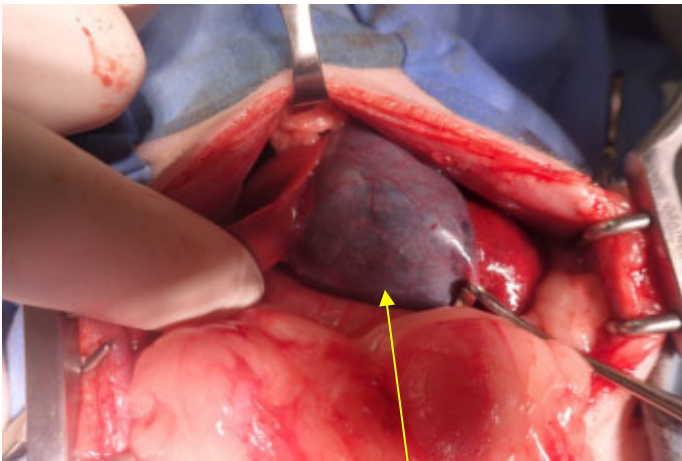
胆嚢切除手術



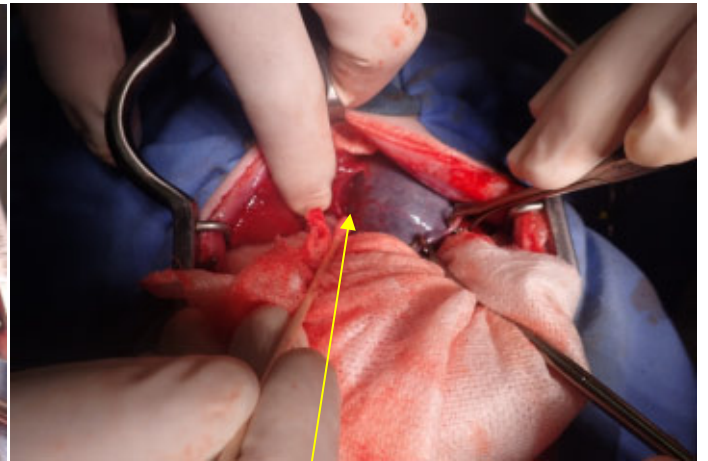
皮下組織をレーザーメスにて切開



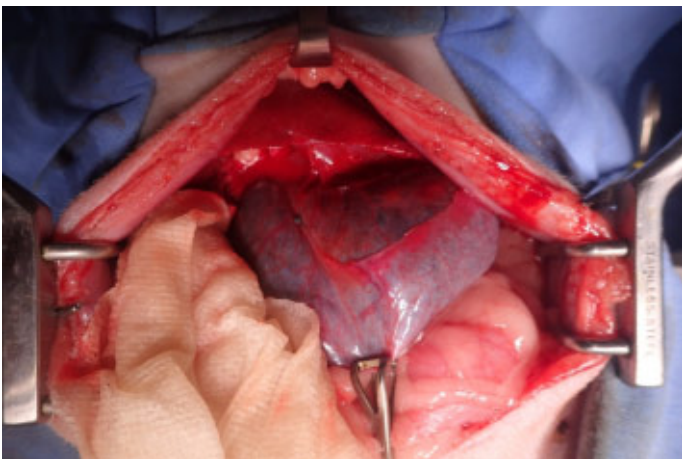
開腹時肝臓の腫大を確認



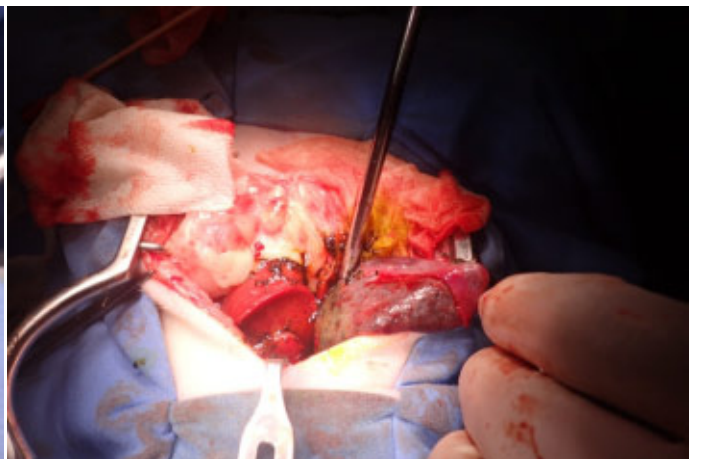
胆嚢の腫大 胆嚢壁の肥厚



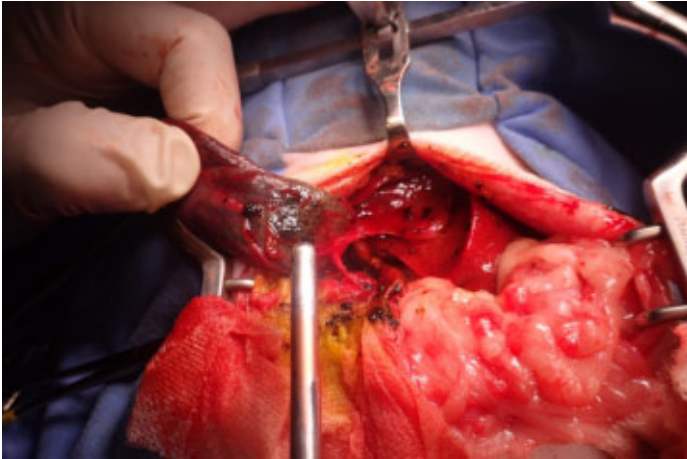
肝臓から胆嚢を分離



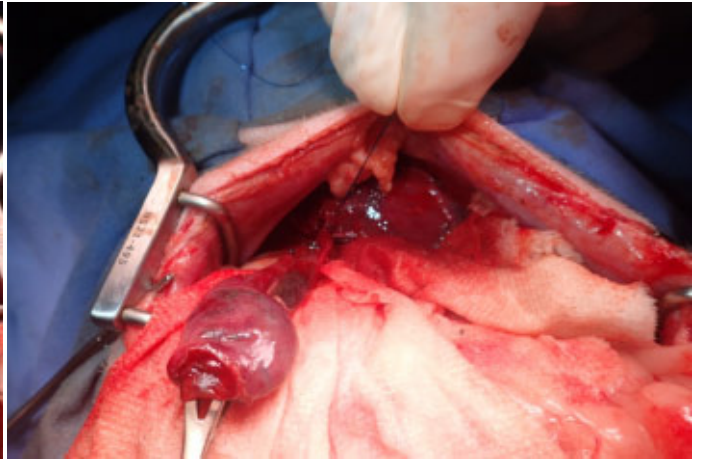
胆嚢を分離中



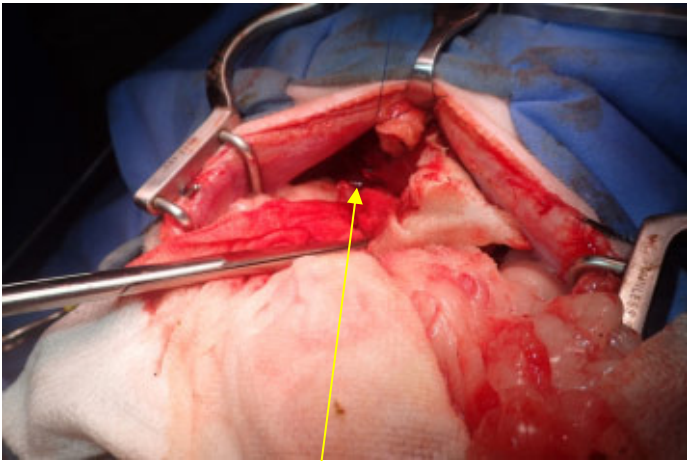
胆嚢頸部の破裂



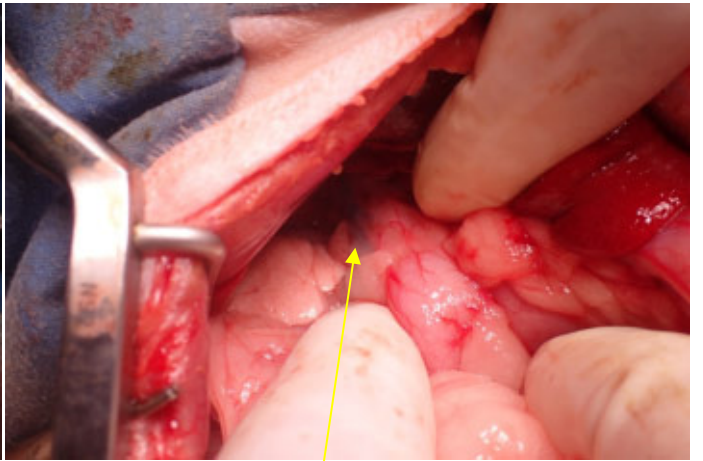
胆汁の吸引



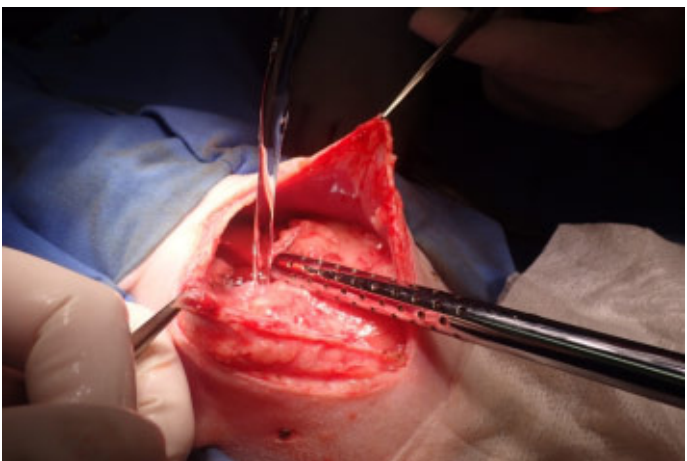
洗浄後胆嚢を底部にて切除



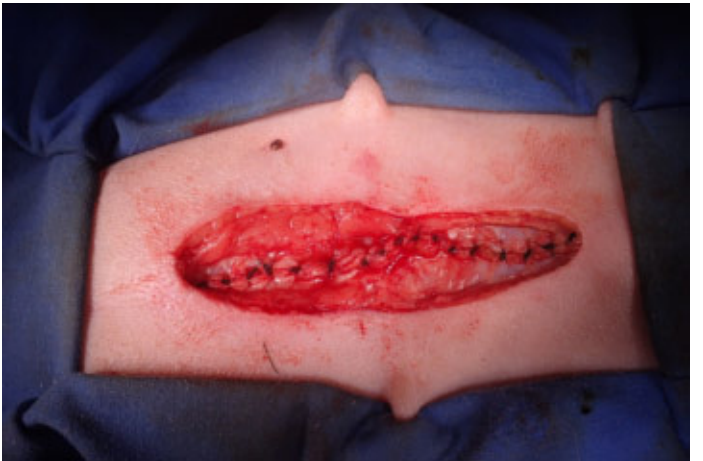切除後



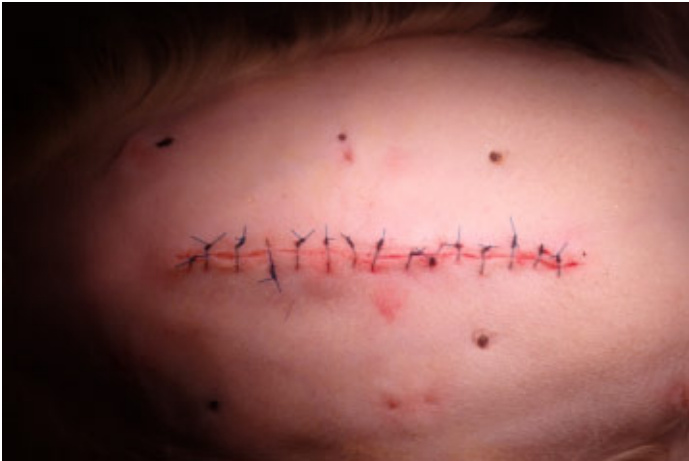総胆管の確認



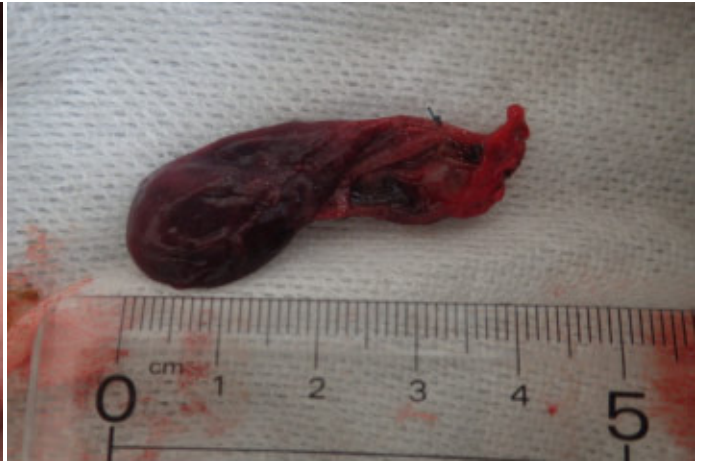腹腔内の洗浄



腹膜縫合



皮膚縫合



切除胆嚢

