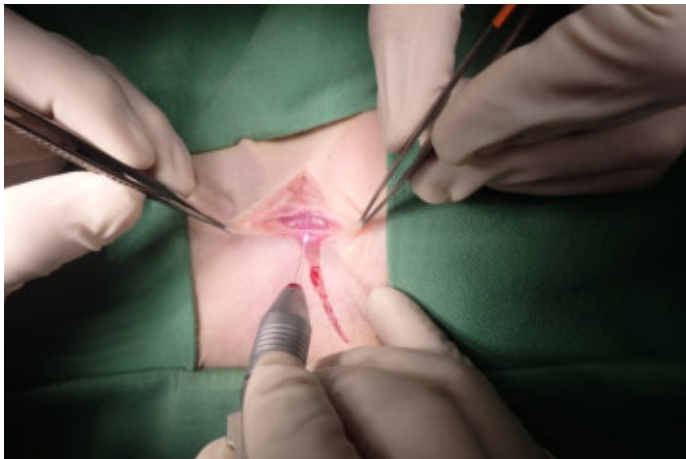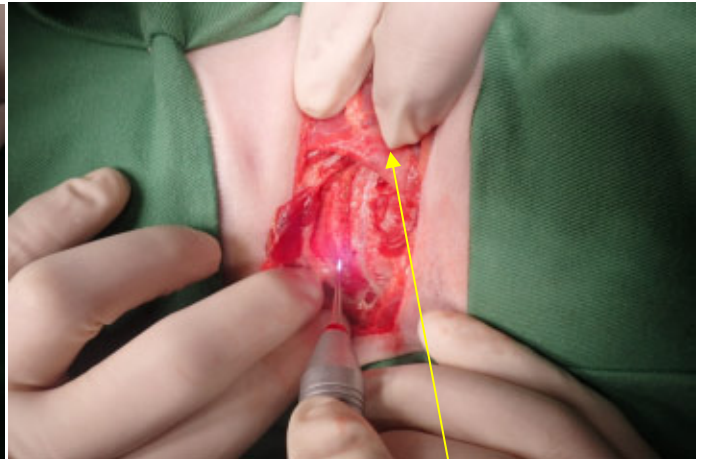


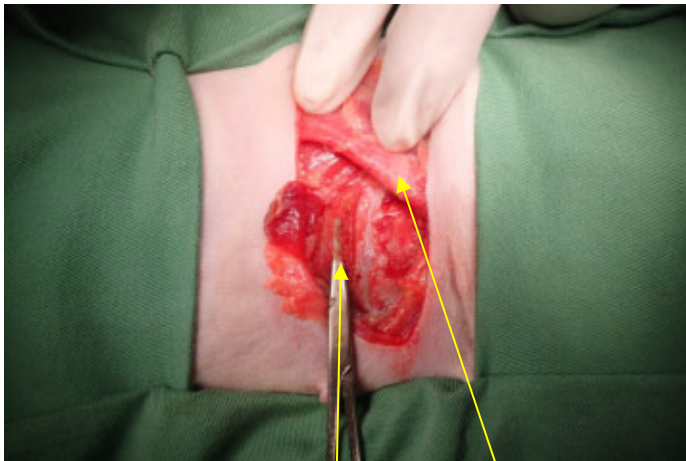
右肺前葉腫瘍切除手術



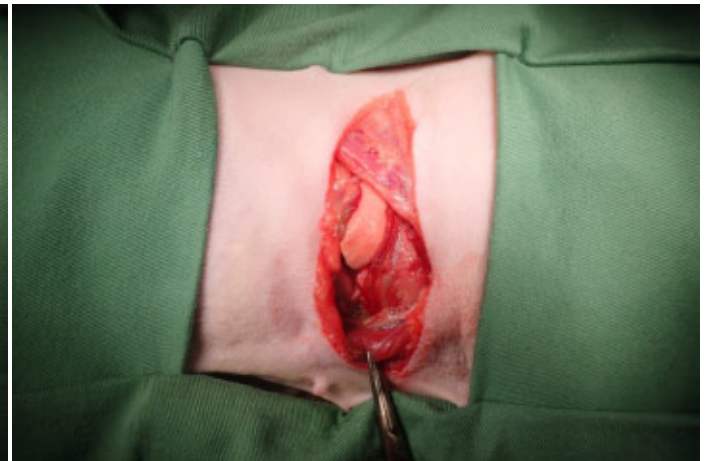
肋骨大 4-5 肋間切開に向けてレーザーメスにて皮下組織切開



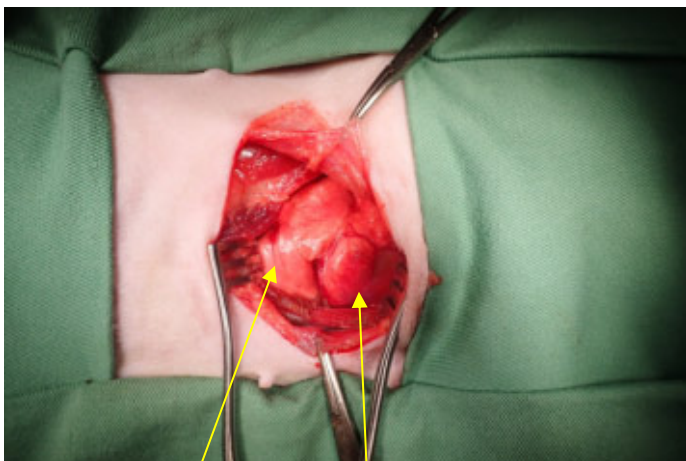
胸膜直上 広背筋、腹鋸筋切開なし



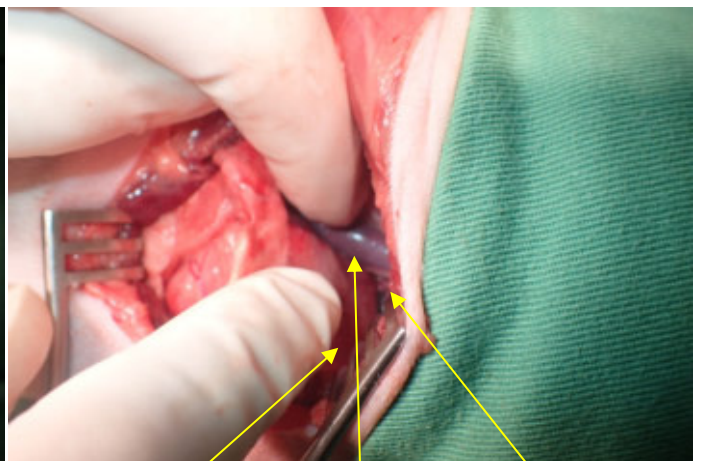
胸膜切開 広背筋



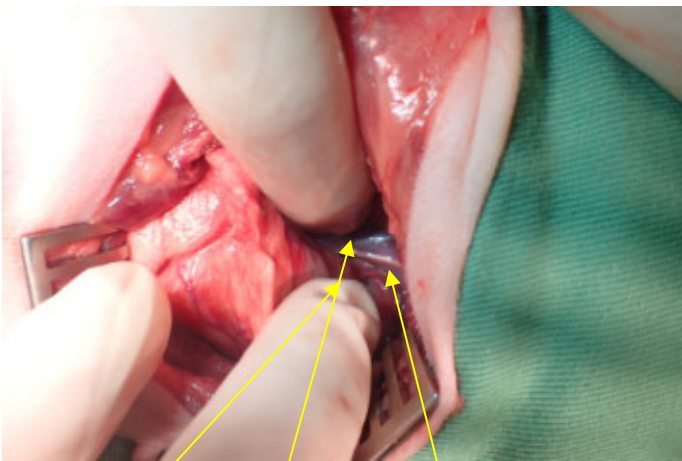
正常な前葉部分



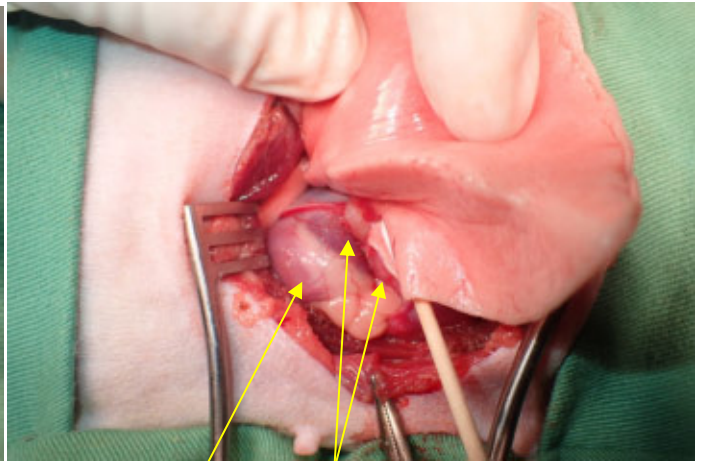
正常前葉 前葉腫瘍病変



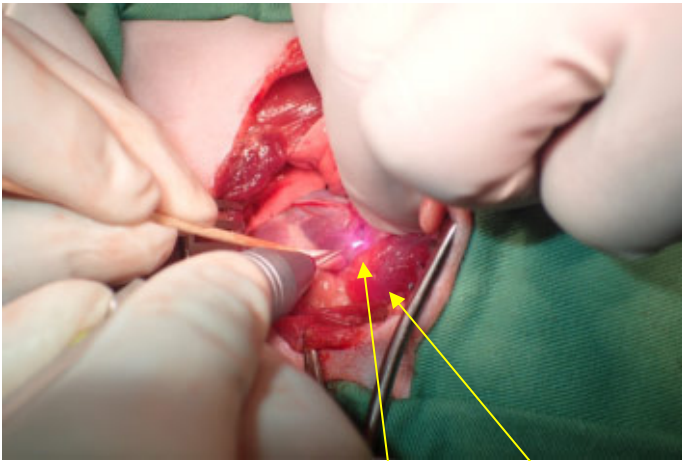
腫瘍前方底部癒着 前大静脈 横隔神経



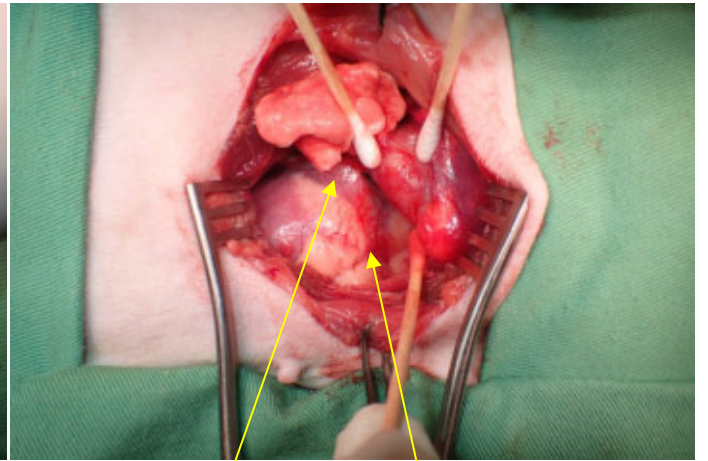癒着部位 前大静脈 横隔神経



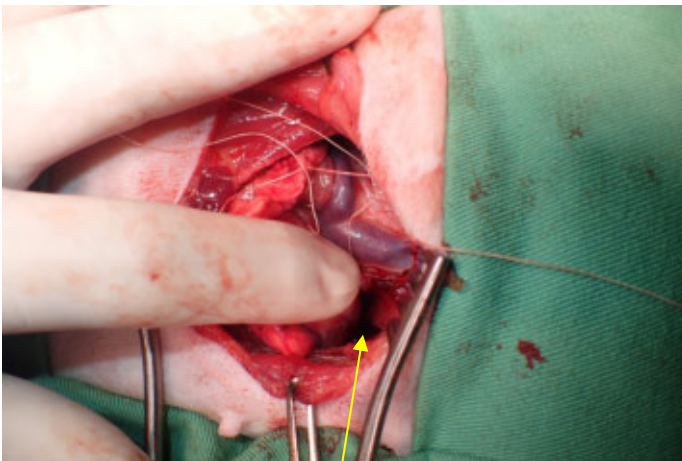
心臓 後方癒着部位



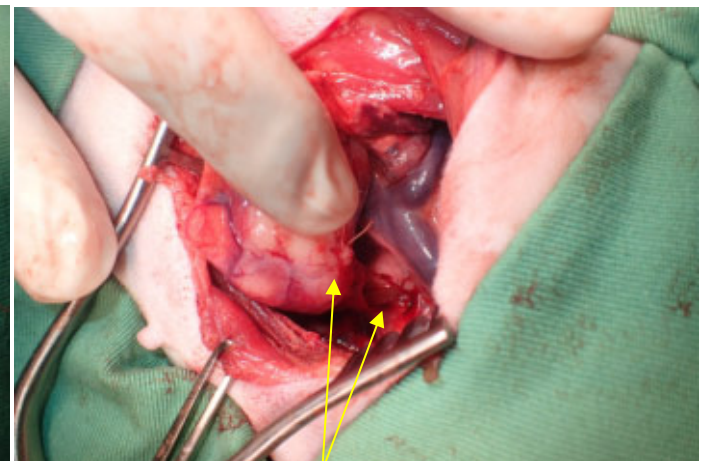
心膜との癒着部位を剥離 心臓



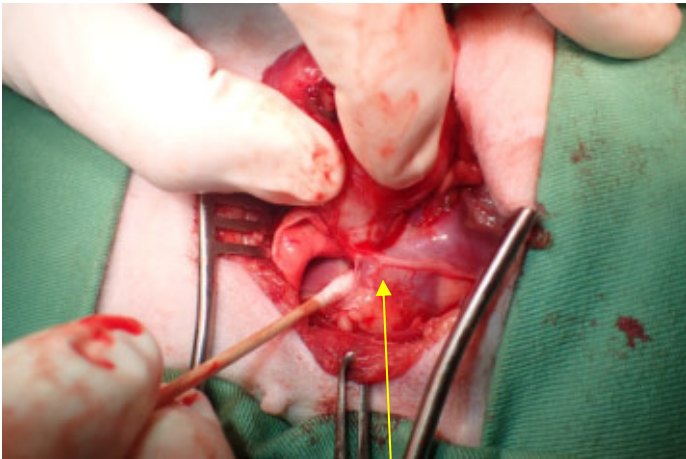
横隔神経と癒着部位 心膜との癒着部位を剥離



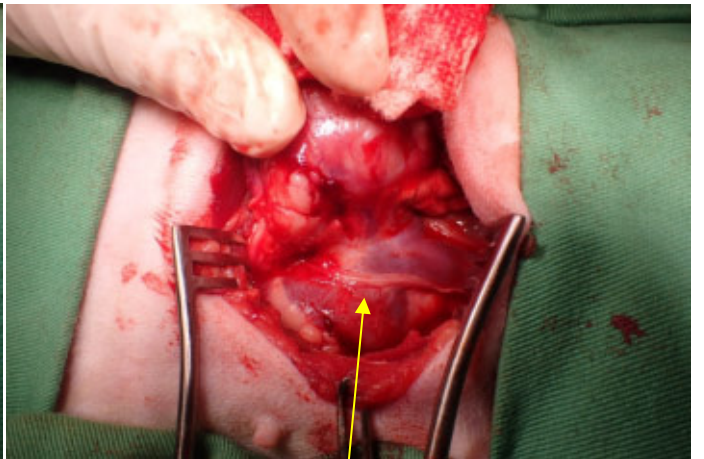
前方癒着部位の結紮離断（やや太い血行が多いため）



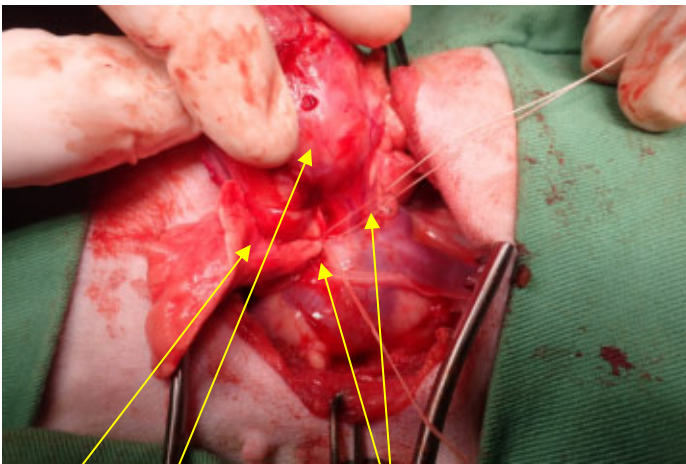
結紮離断終了



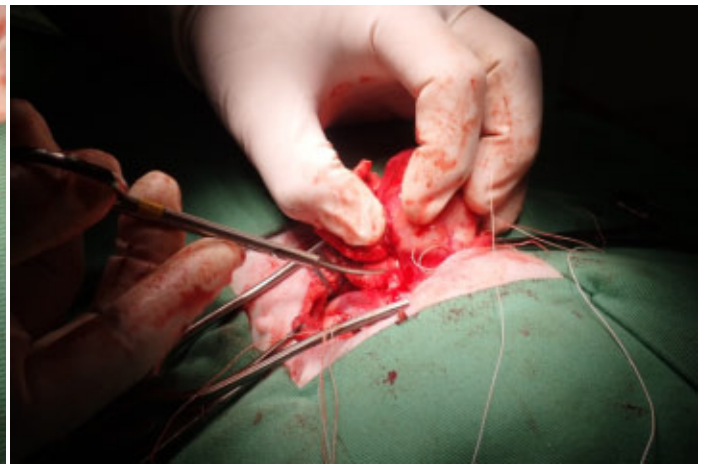腫瘍と横隔神経との癒着を剥離



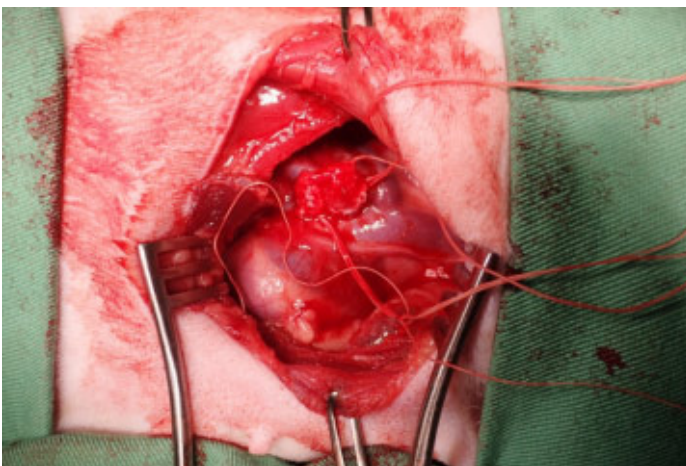
横隔神経温存し腫瘍から剥離



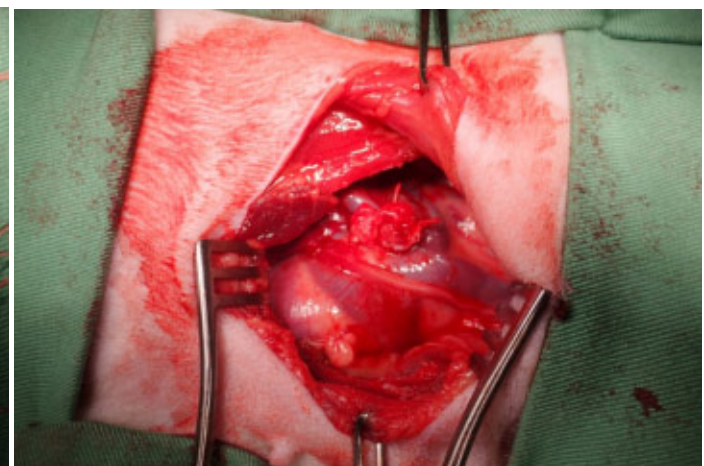
右肺中葉と前葉の肺動静脈、気管支を結紮離断

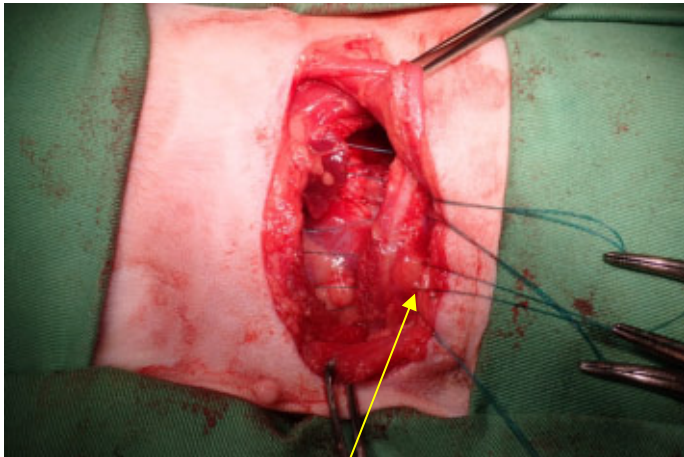


結紮後切除

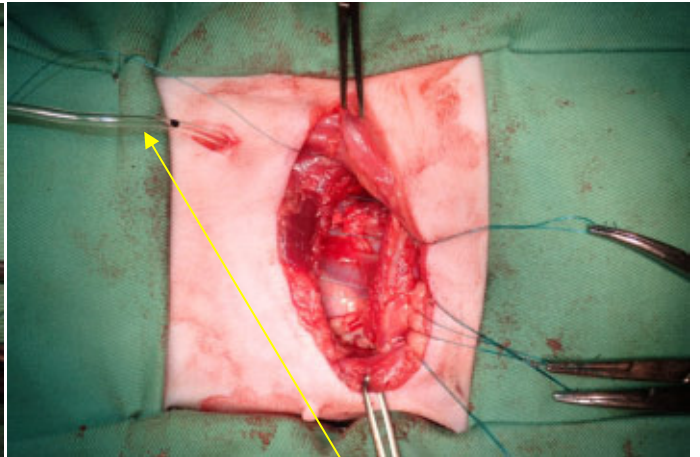


切除後胸腔内を洗浄

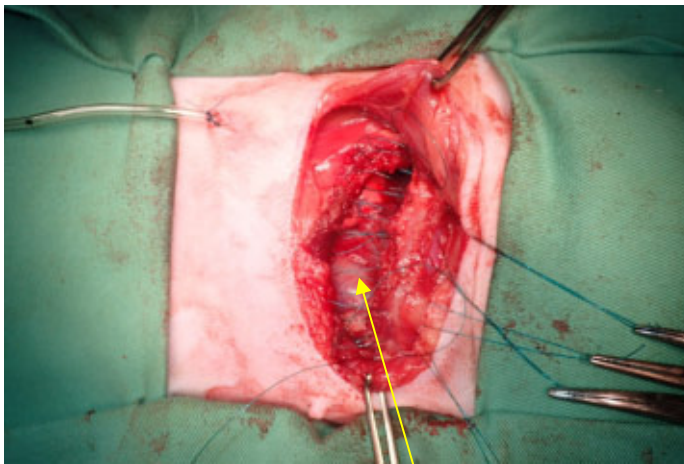




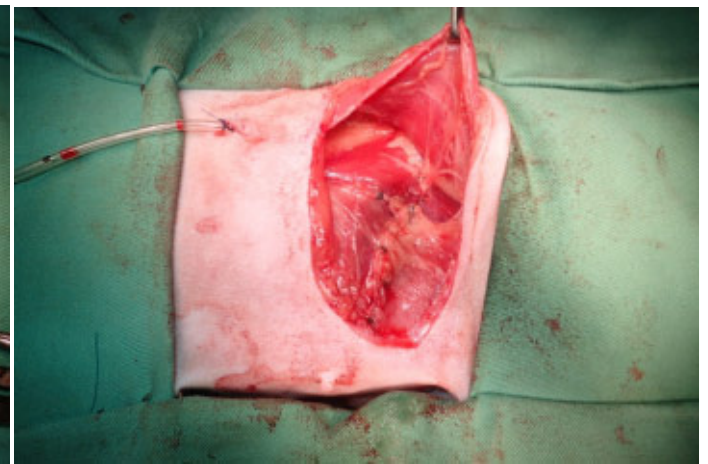
肋間に支持糸



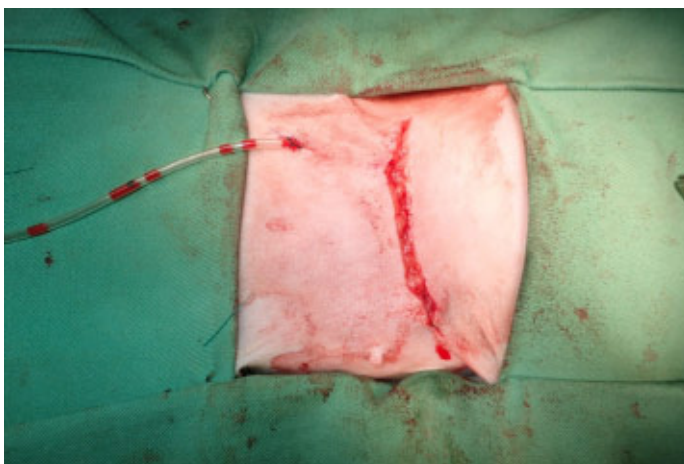
胸腔ドレーンを留置



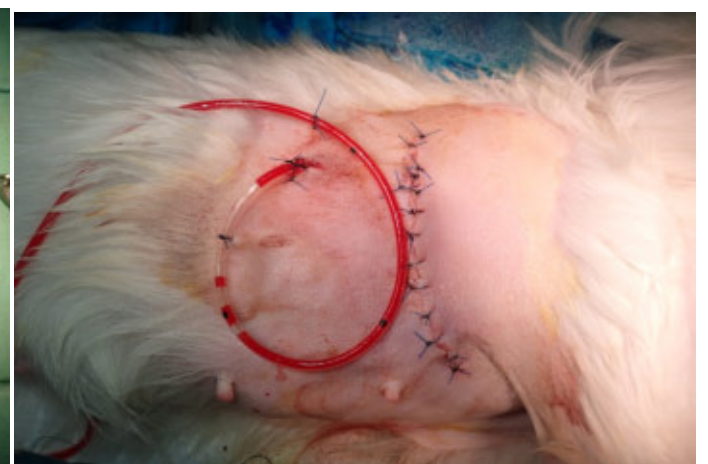
肋間筋と胸膜の連続縫合



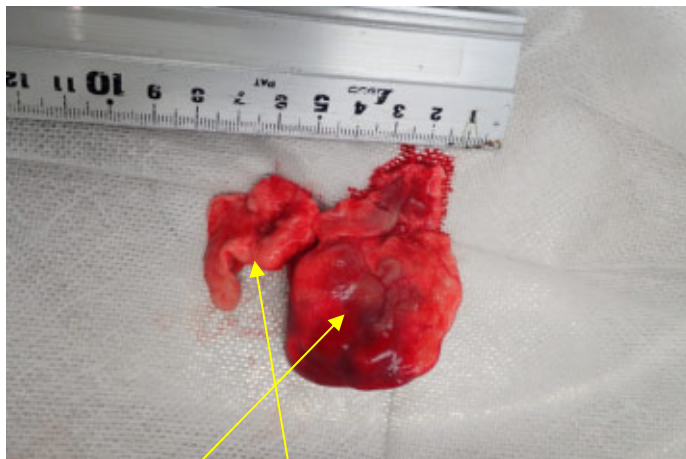
閉鎖終了



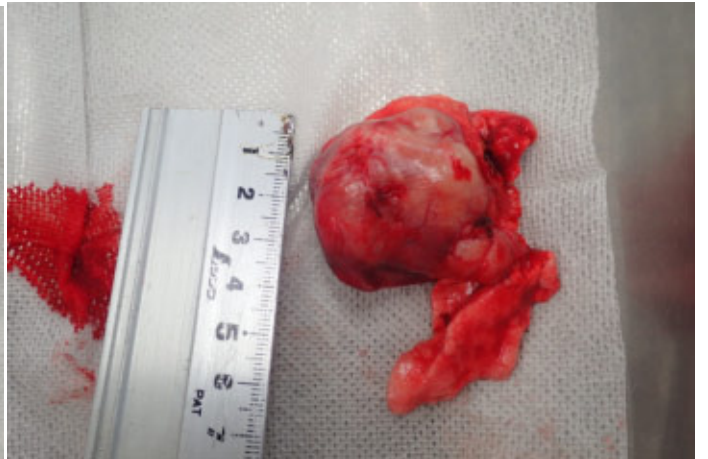皮下縫合



皮膚縫合終了



右前葉と中葉を切除 外側



内側