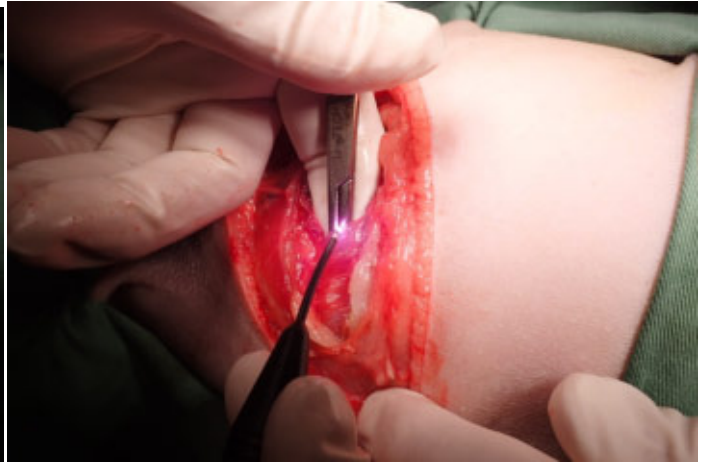
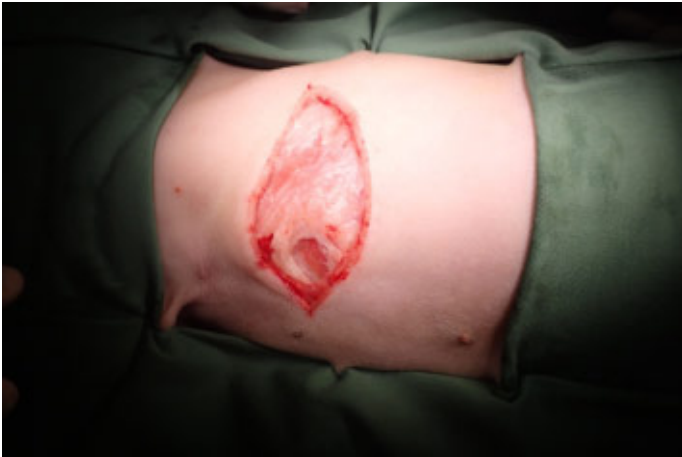
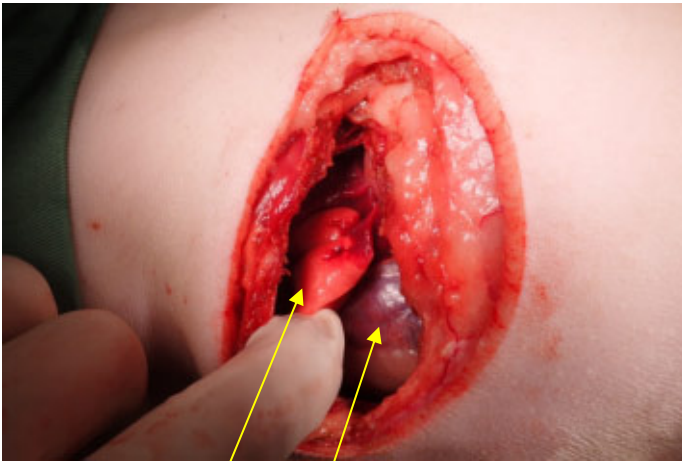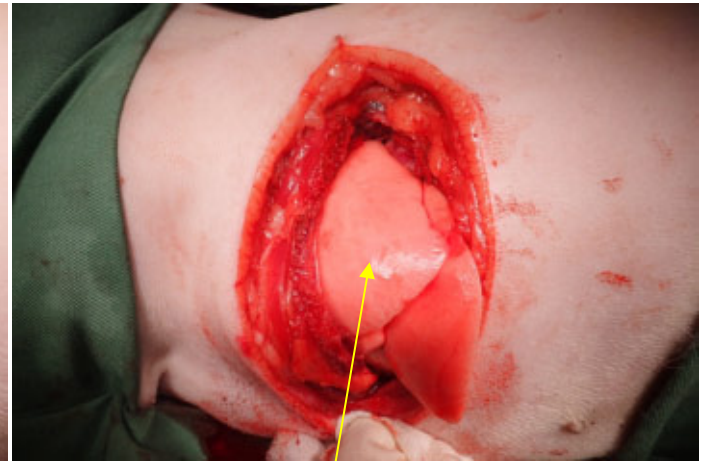
左肺後葉切除手術



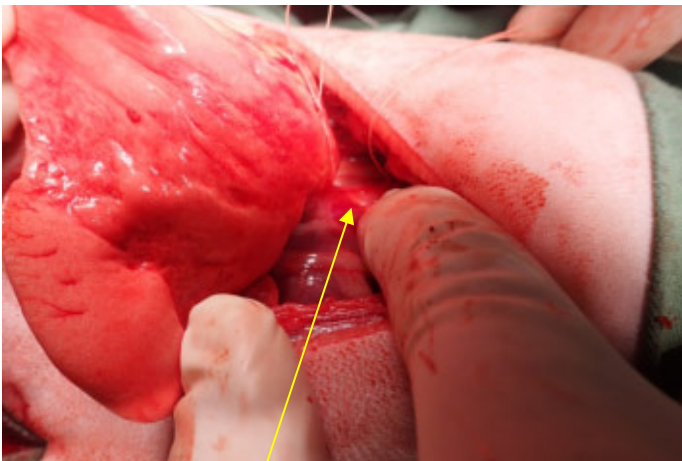
皮膚切開後レーザーメスにて肋間筋を切開し開胸



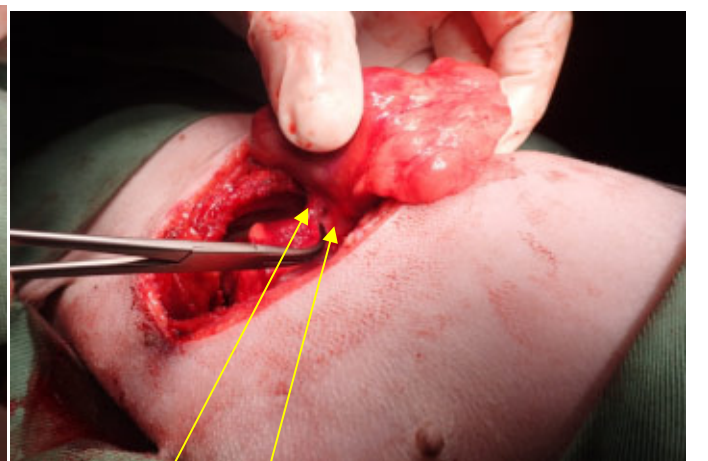
正常肺 腫瘍



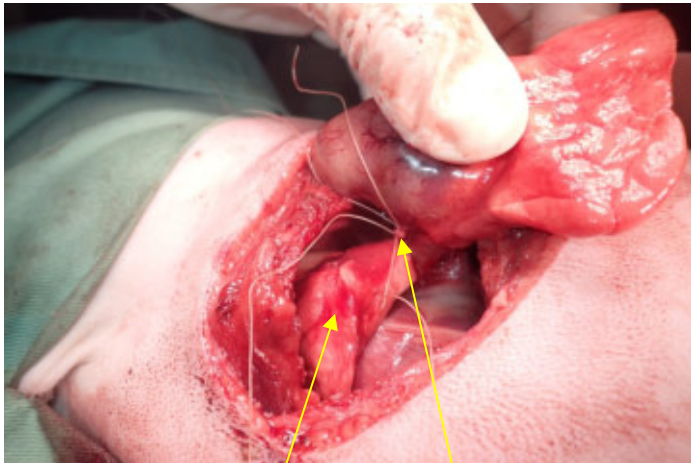
正常肺



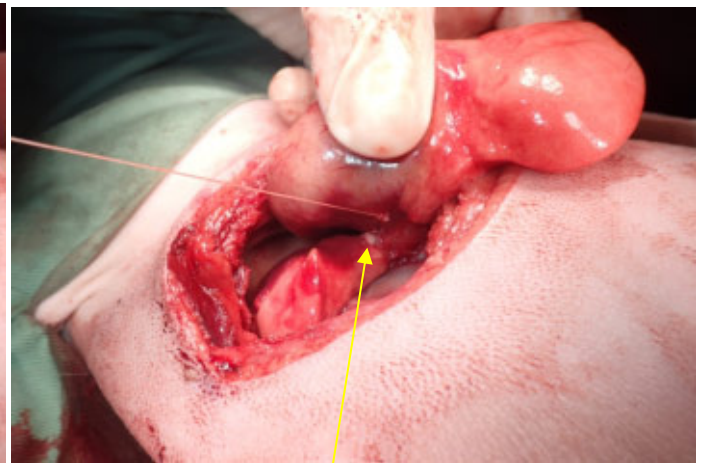
肺どうしの間膜を切開



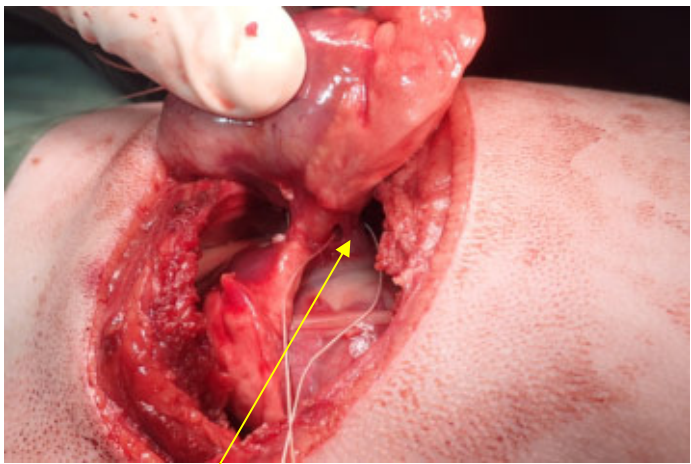
肺動脈を気管から分離し結紮



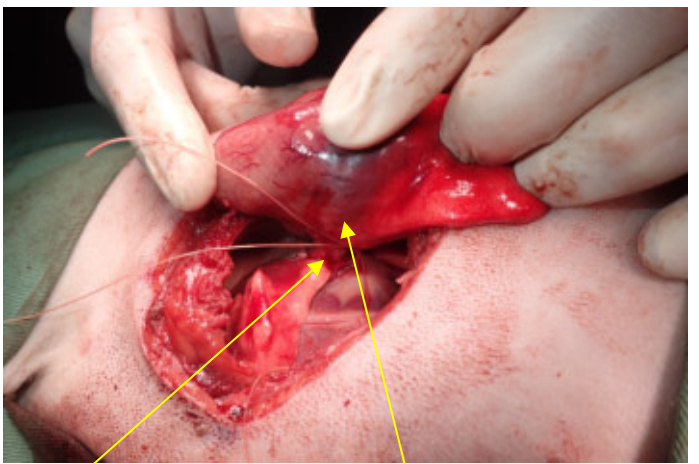
残存左肺前葉 この間を切断 (0.05mm)



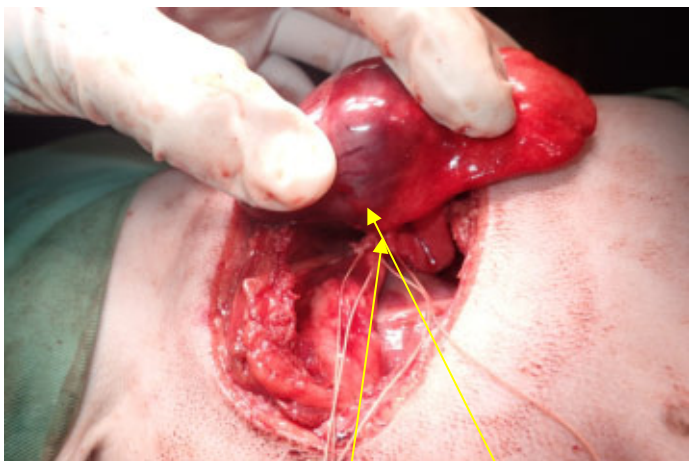
切断終了



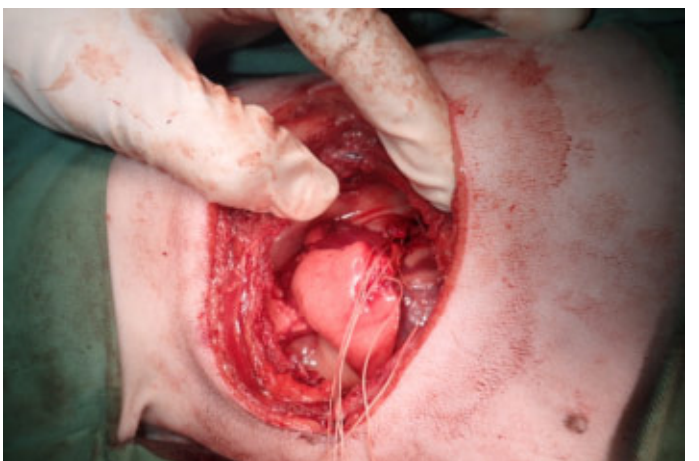肺静脈を結紮 離断



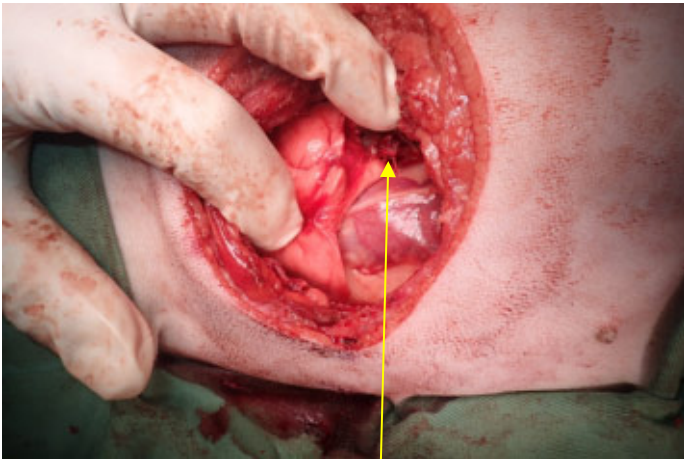
気管を結紮 離断 (腫瘍は切断面ギリギリ)



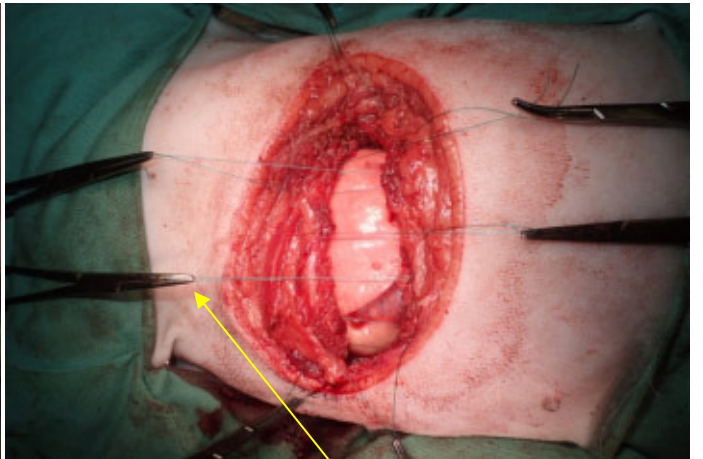
ここを切断 腫瘍部位



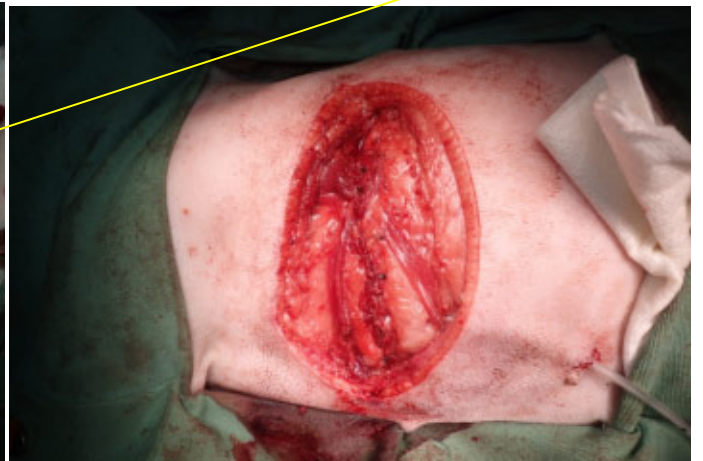
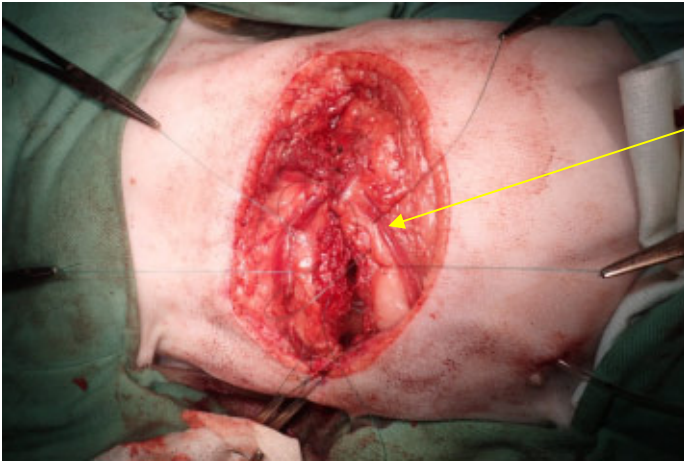
切除終了



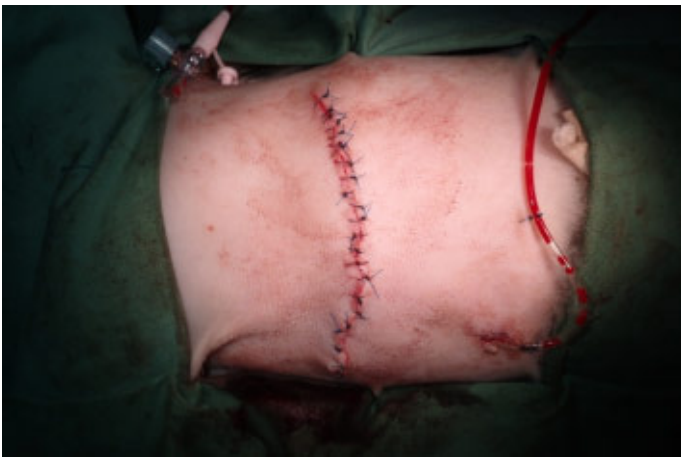肺を膨らまして気管からの空気の漏れの確認



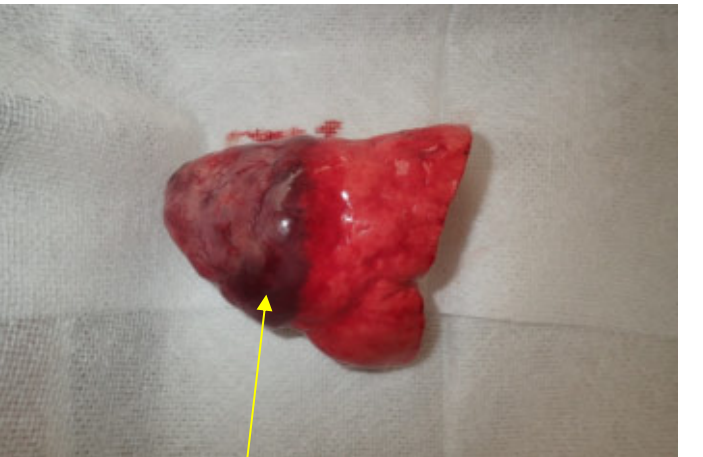
肋間に糸をかけ減張 肋間筋を連続で縫合



閉胸終了



皮膚縫合終了 胸腔を陰圧にするドレーン



腫瘍部位