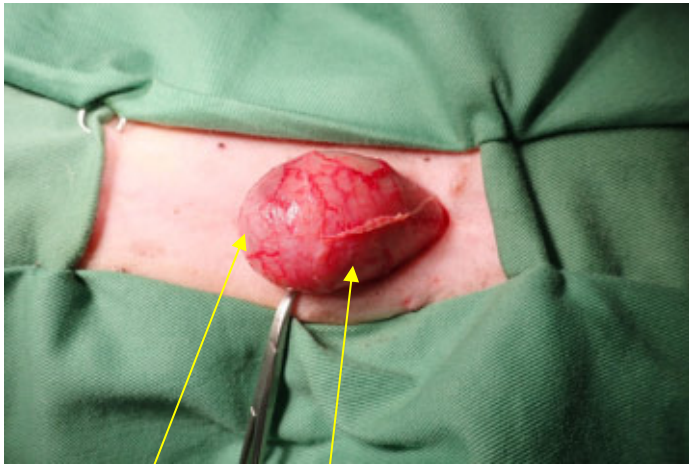
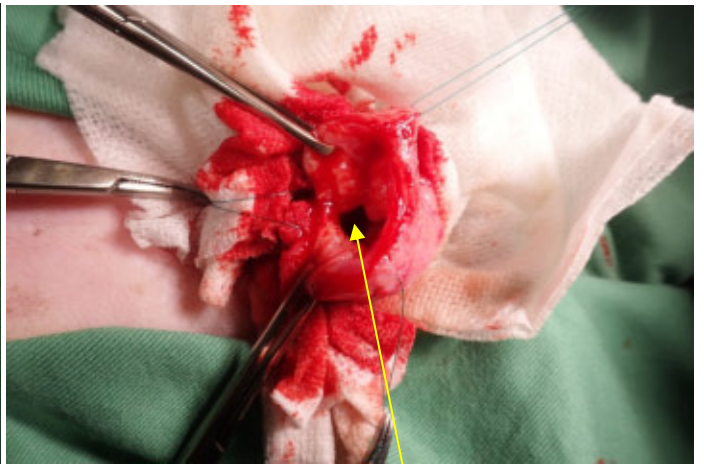


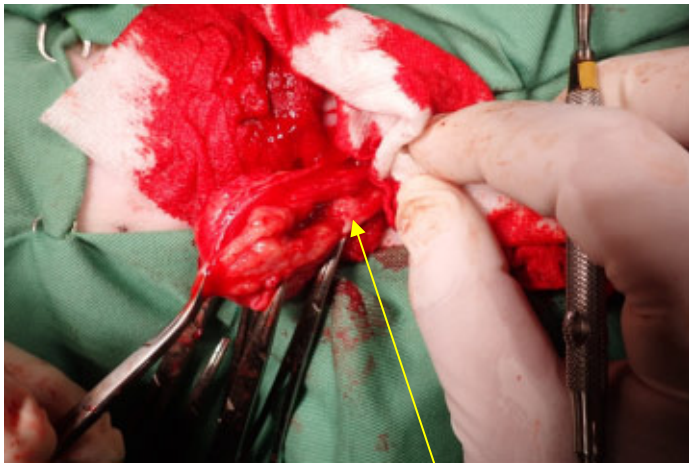
膀胱癌切除手術



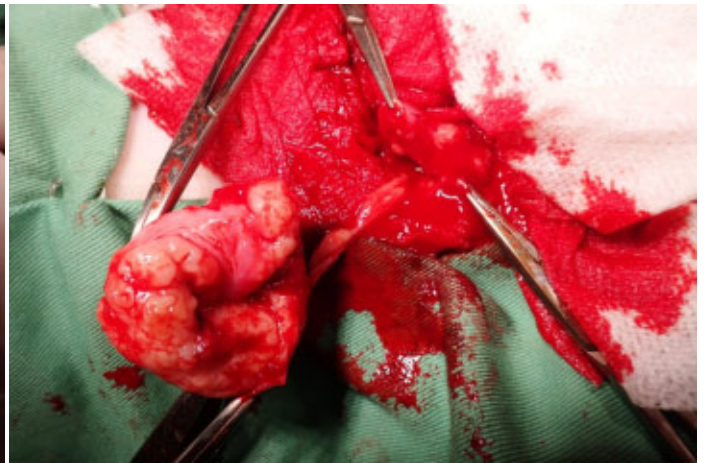正常膀胱 異常膀胱（硬固）



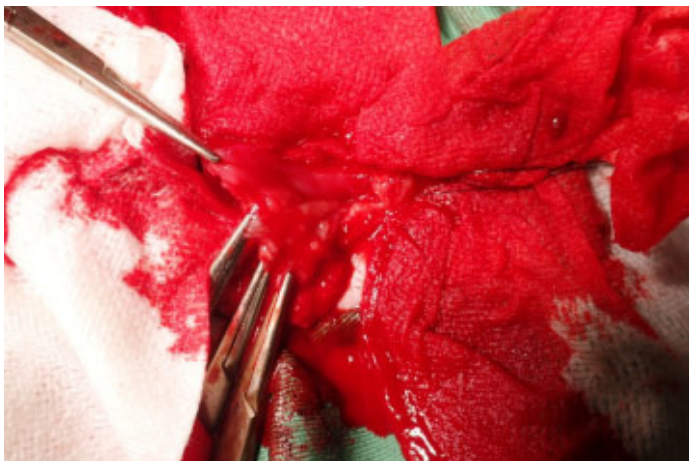
膀胱内腔 腫瘍組織



膀胱三角部（尿管開口部）を確認



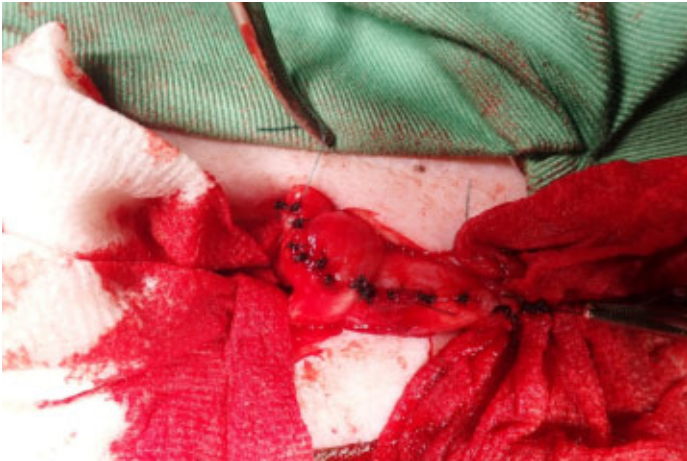膀胱を牽引し正常粘膜で切除



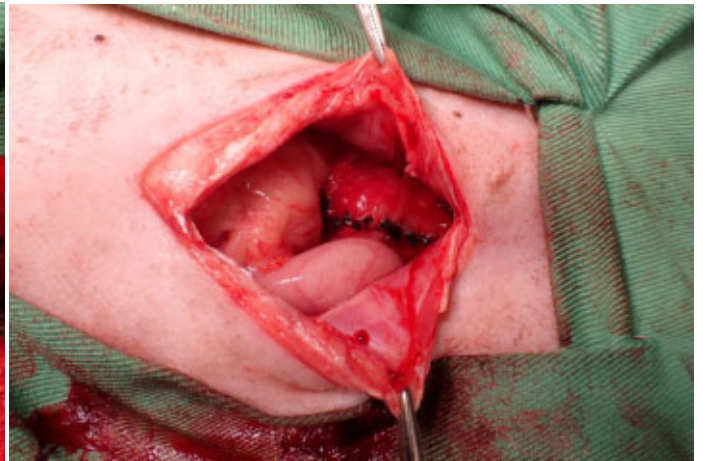
切除後



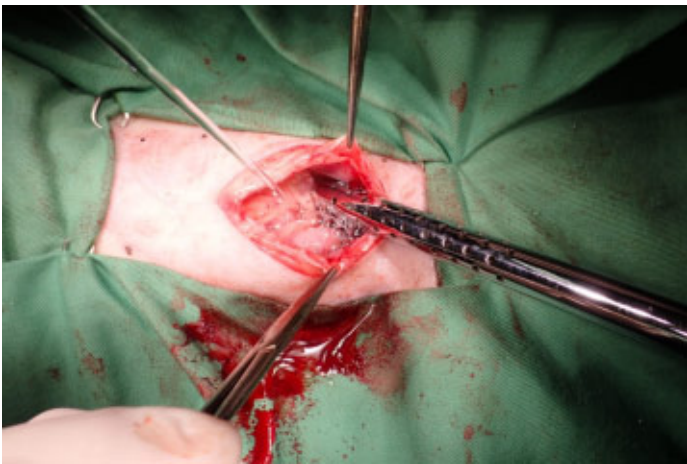縫合



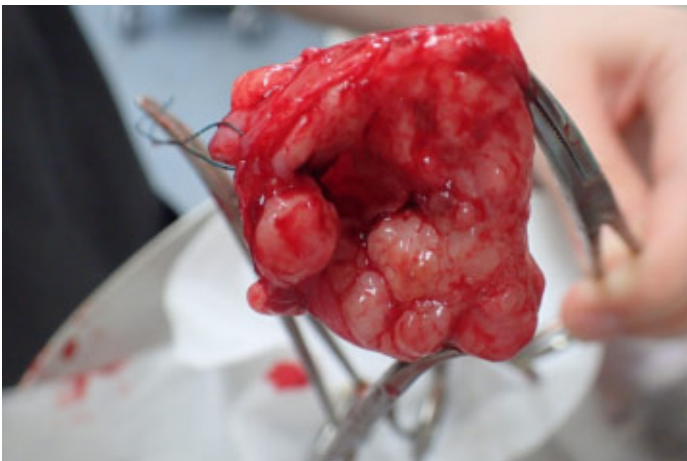
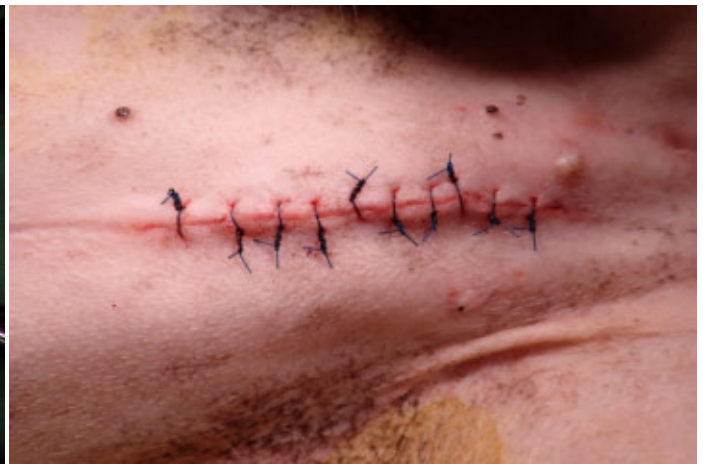縫合終了



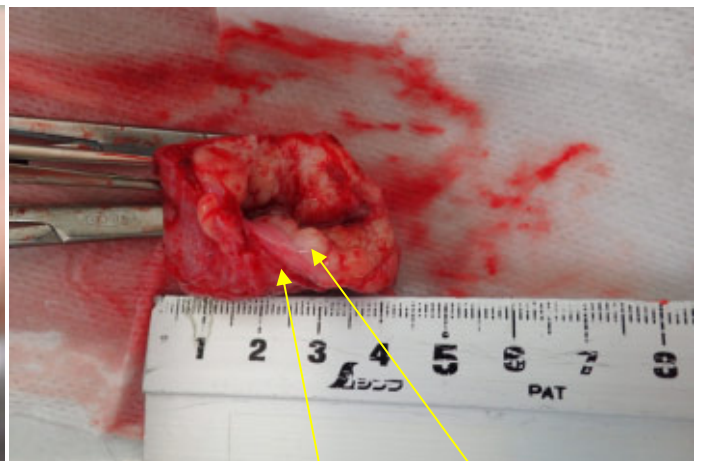
洗浄後腹腔内へ



腹腔内も洗浄



膀胱内腔癌組織



正常粘膜 異常粘膜